

Approach to X ray in Cardiac diseases

Dr M Sudhakar Rao

MD DM FACC FESC FSCAI

Consultant Cardiologist

Manipal hospital, Old Airport Bangalore

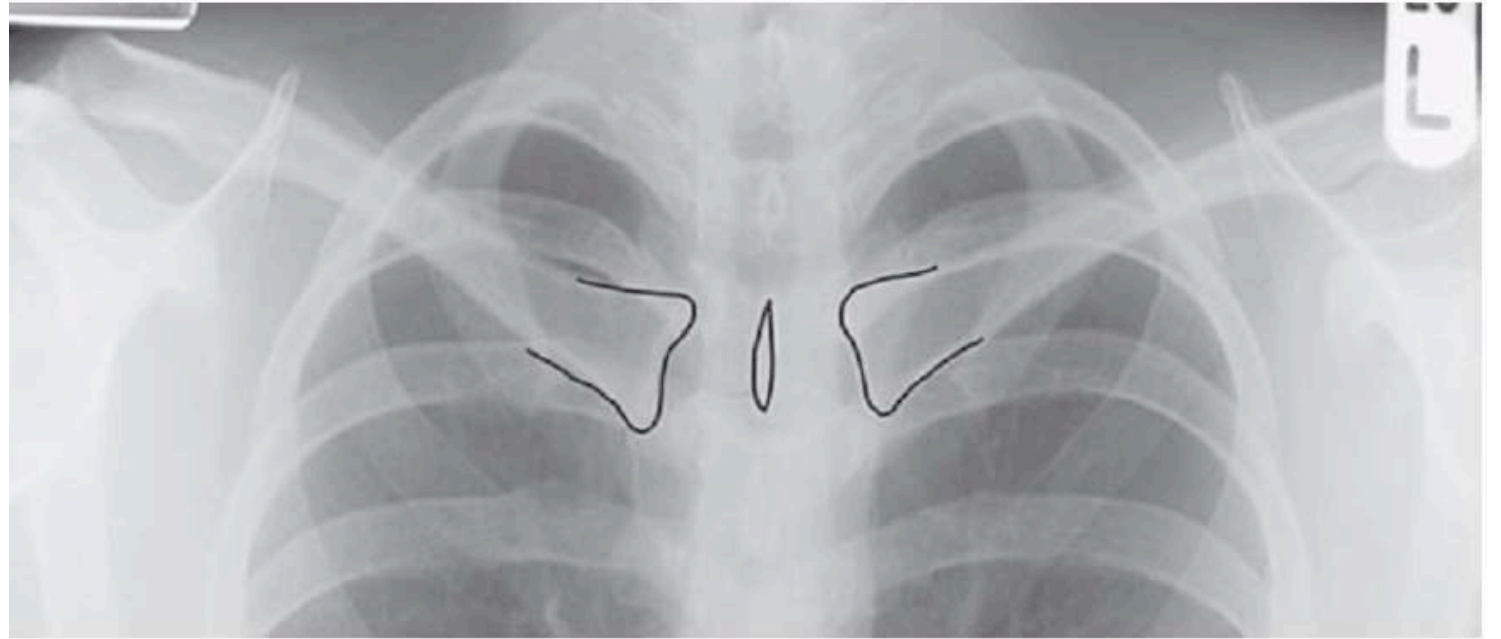
Ex Associate Professor Cardiology(KMC Manipal, MAHE)

Adjunct Faculty , MCHP, MAHE, Manipal

Outline of the talk

- Rotation
- Inspiratory vs Expiratory Film
- Projection
- Exposure
- Structures seen in anterior/lateral view
- Diagnosis of chamber enlargement
- Diagnosis of PAH and PVH
- Diagnosis of aortic enlargement
- X ray in common diseases

ROTATION



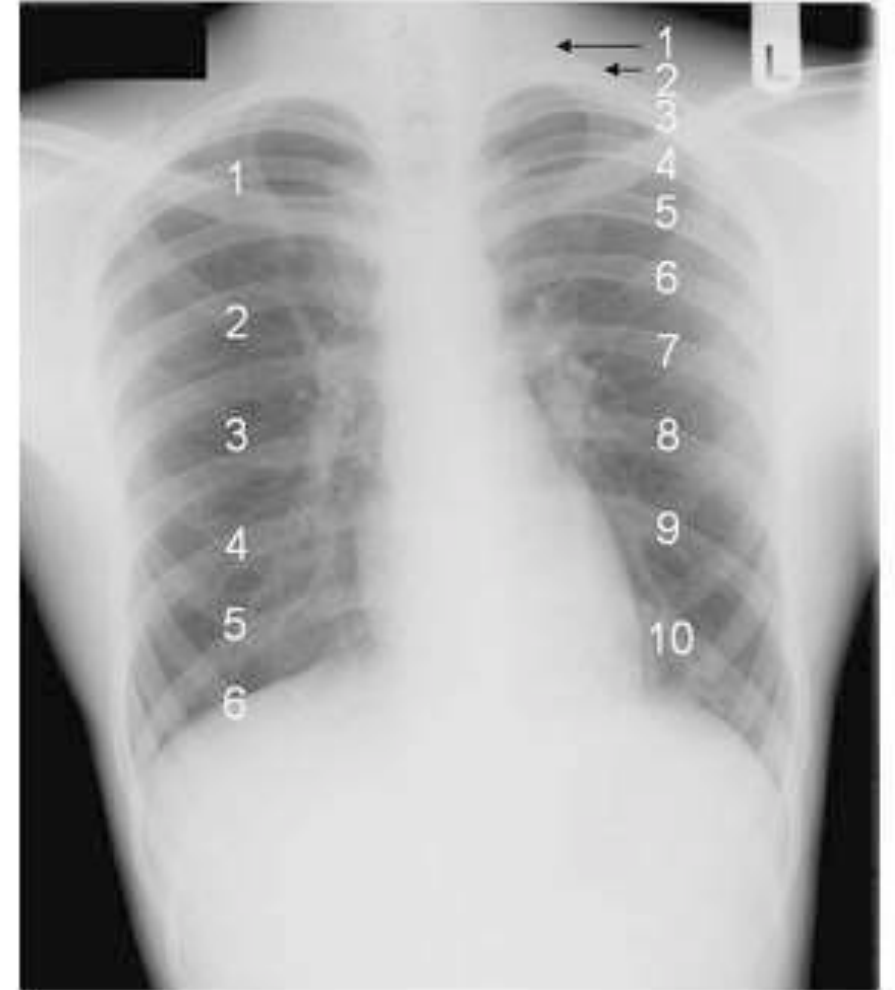The medial ends of both clavicles should be equidistant from the spinous process of the vertebral body projected between the clavicles

Inspiratory vs Expiratory Film

Adequate inspiratory effort – five to seven complete anterior or ten posterior ribs are visible

Poor inspiratory effort - fewer than five anterior ribs

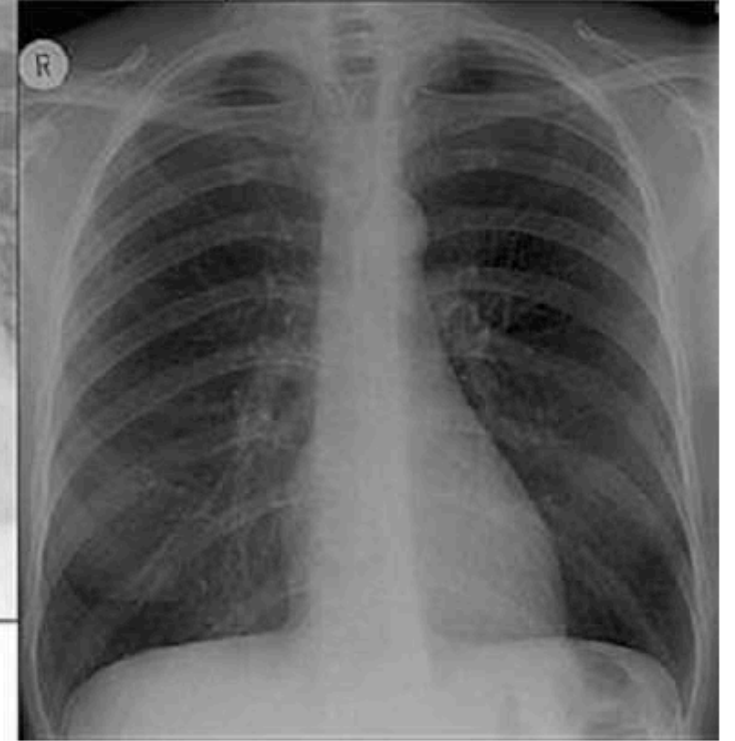
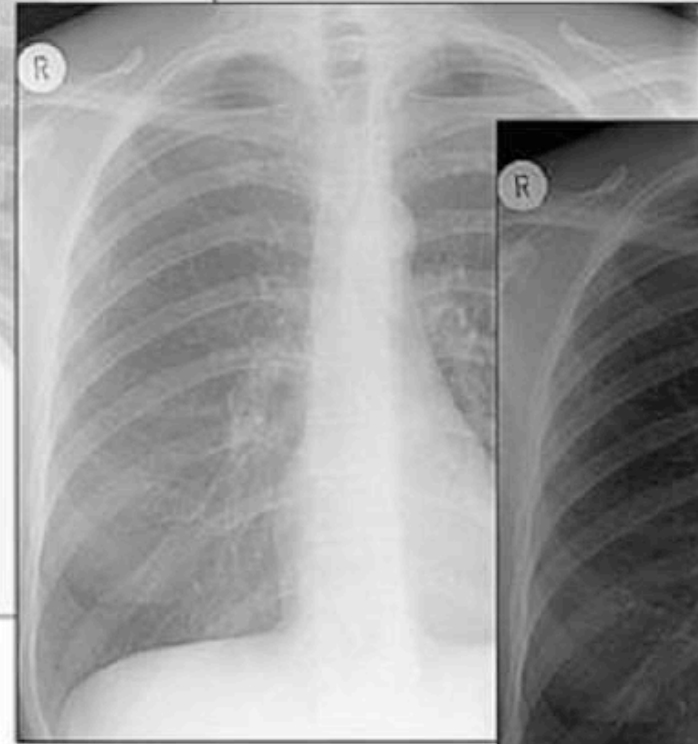
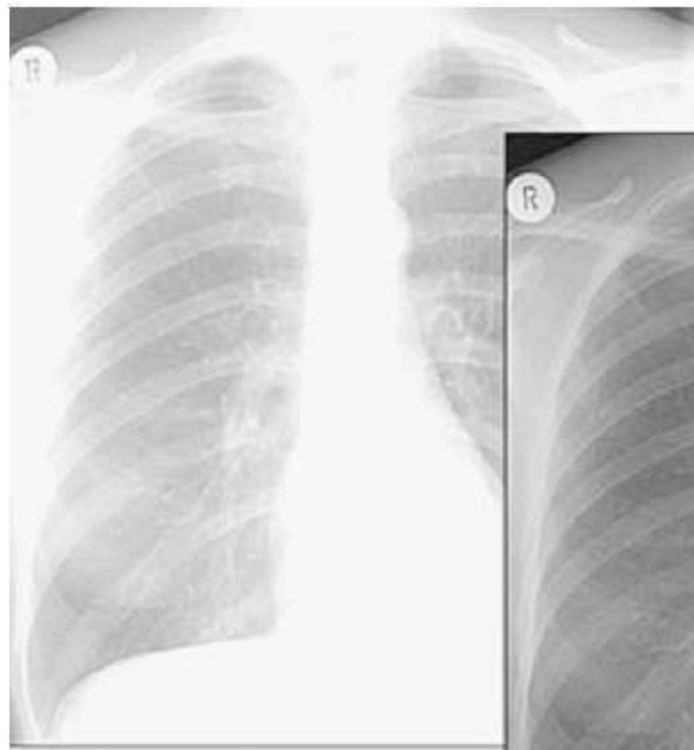
Hyper inflated lung-more than seven anterior ribs



Projection

PA VIEW	AP VIEW
In erect patients	In supine patients
Vertebral spines more prominent	Vertebral bodies clear
Scapulae clear of lungs	Scapulae overlap
Clavicles are horizontal	Clavicles are oblique
Gas bubble in fundus with a clear air fluid level	Gas bubble in antrum
No apparent cardiomegaly	Apparent cardiomegaly
Overriding of clavicle and first rib	Not prominent
Clavicle companion shadow	Absent

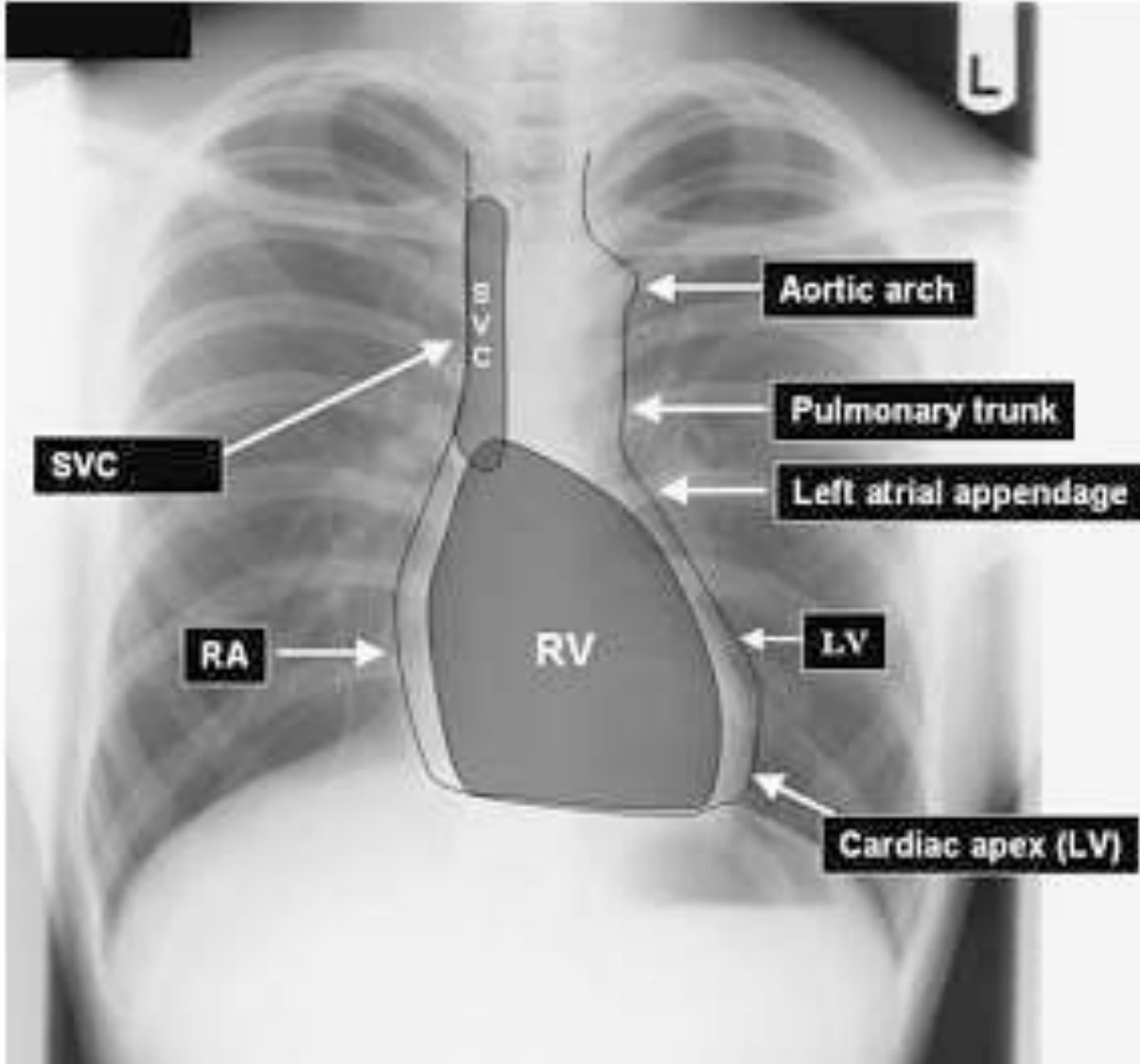
Exposure



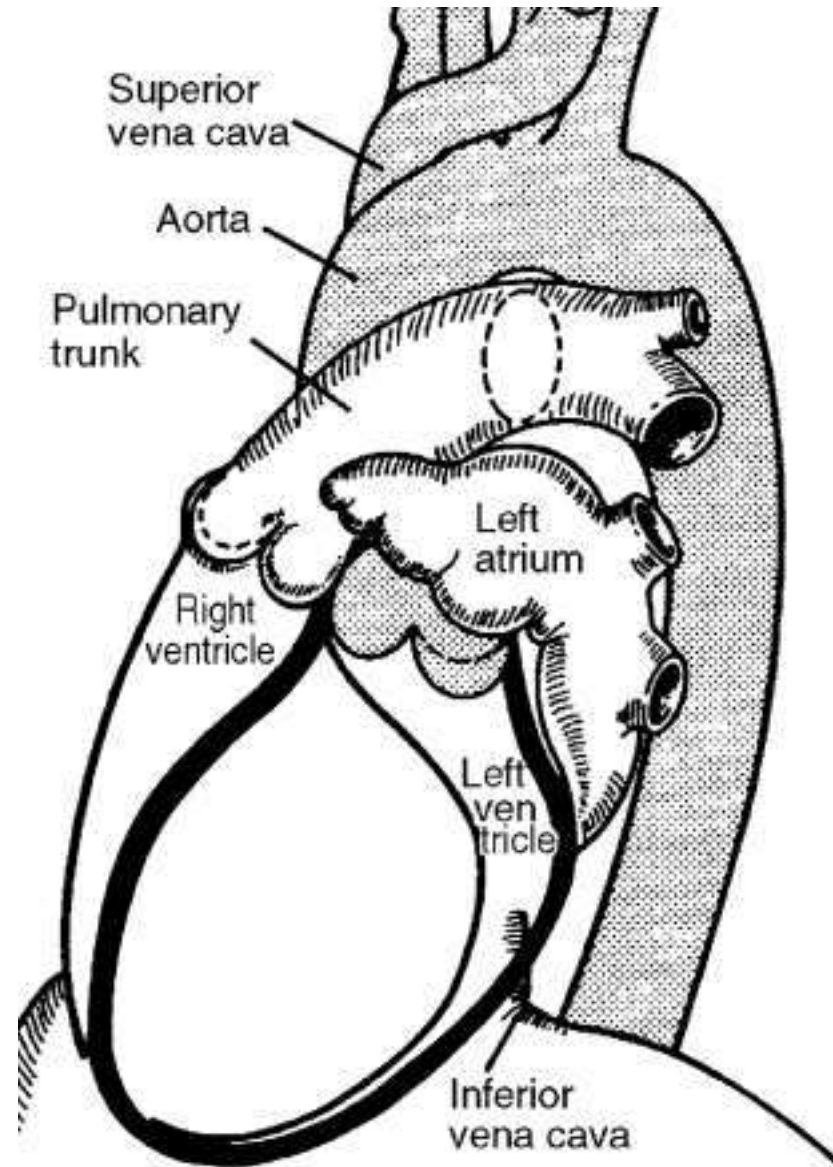
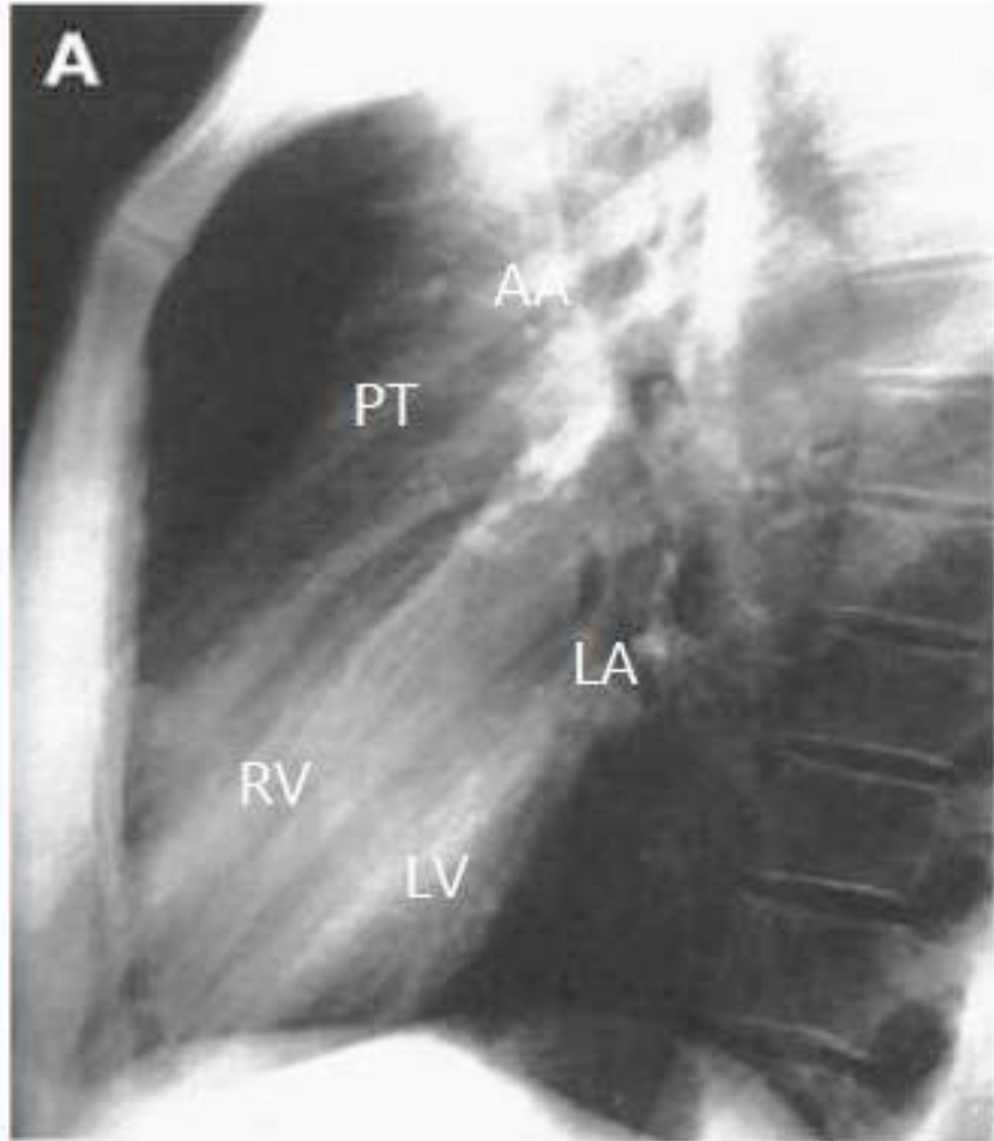
Normal exposure - the vertebral bodies should just be visible at the lower part of cardiac shadow

Underexposed -If the vertebral bodies are not visible.

Structure seen in Anterior view



Structures seen in Lateral view



Cardiomegaly

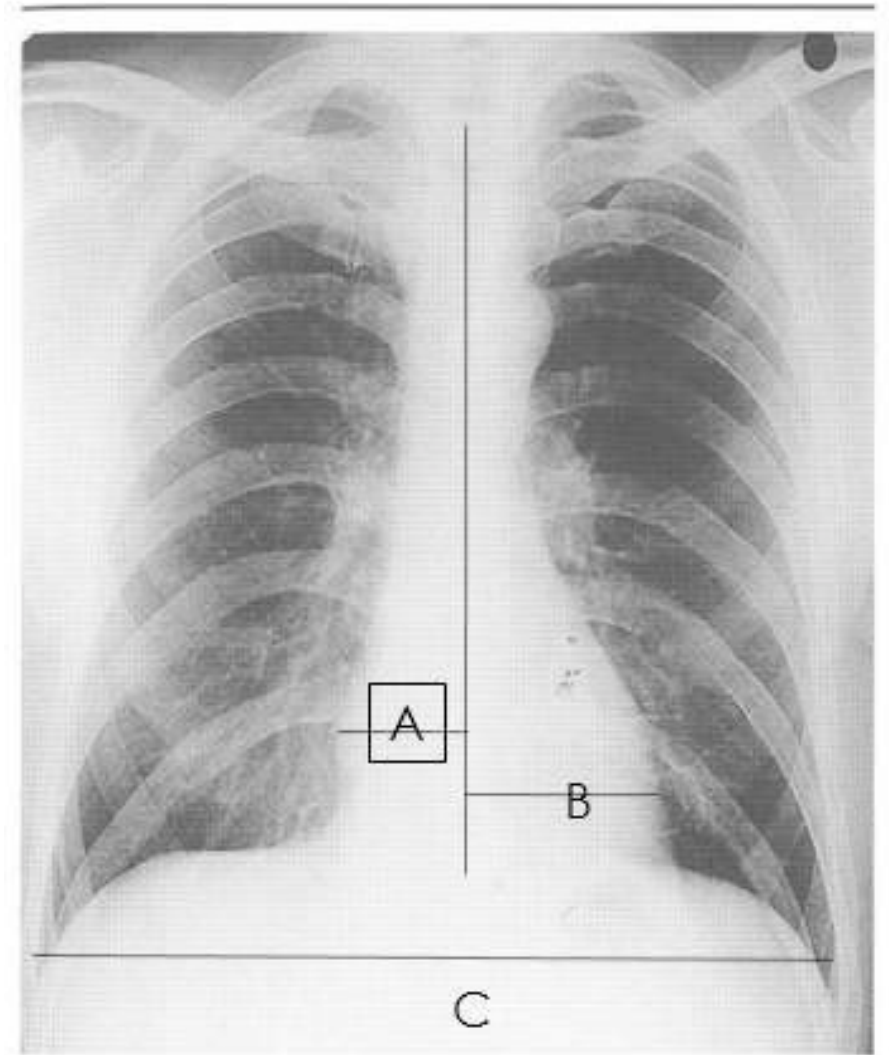
Normally less than 0.55

>0.55 in Adults – Cardiomegaly

>0.60 in Newborns – Cardiomegaly

Any increase in transcardiac diameter > 2 cm compared to old x-ray

In old age and emphysema a transcardiac diameter more than 15.5 cm in males & >12.5 cm in females



Spurious causes of Cardiac enlargement

- Portable AP films
- Obesity
- Pregnant
- Ascites
- Straight back syndrome
- Pectus excavatum

RA Enlargement

- **Vertical Criteria**

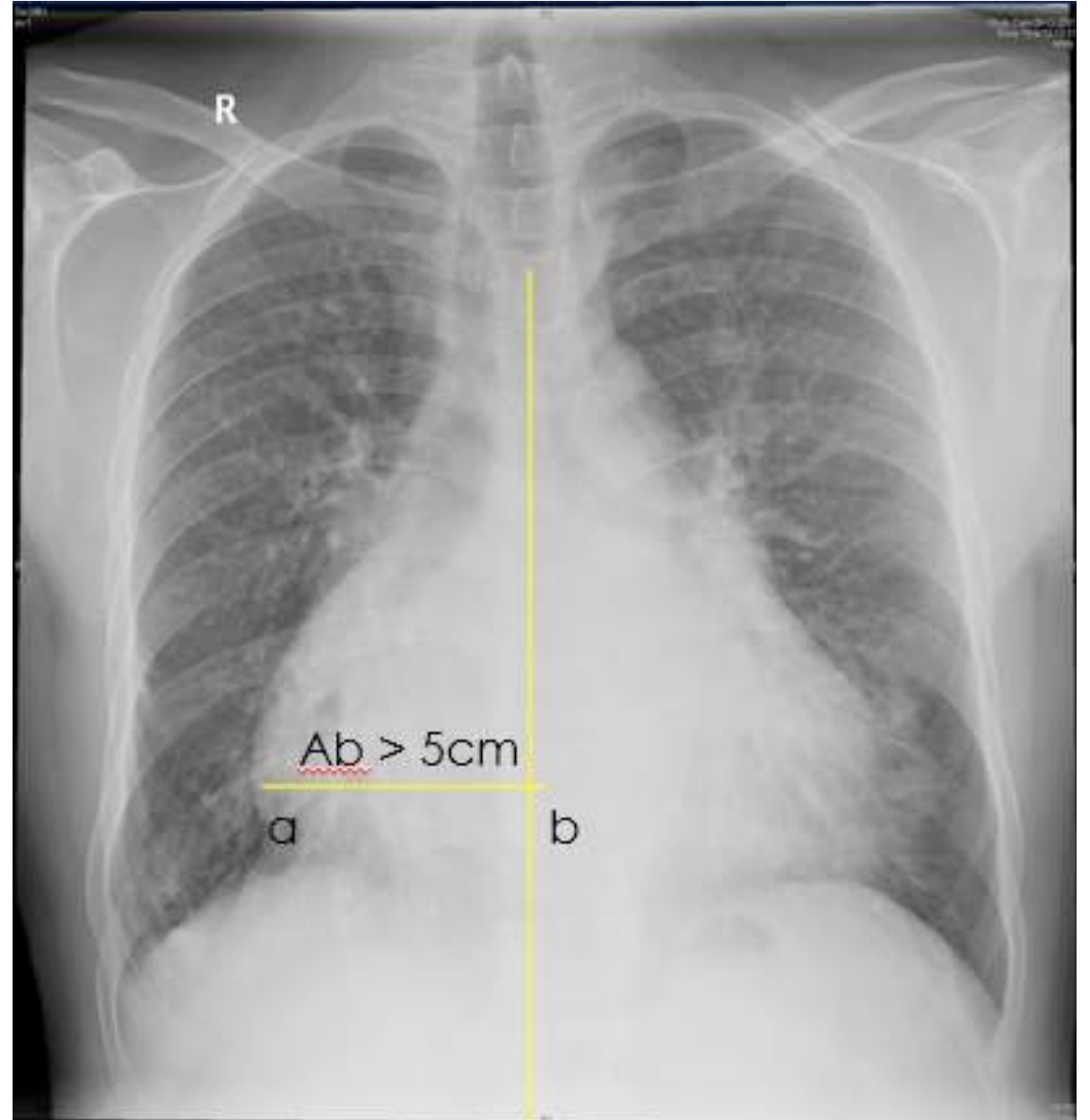
- (i). Rt. Atrial border extends >3 intercostal spaces
- (ii). Rt. Atrial border more than 50 percent of right heart border

- **Horizontal Criteria**

- (i). Rt. Atrial border extending 3.5 cm beyond lateral vertebral border
- (ii). Rt. Atrial border extending 5.5 cm beyond mid vertebral line
- (iii). Right Atrium occupying more than one third of right hemithorax
- (iv). right atrial convexity is more than 50% of the cardiovascular height

Causes of RA enlargement

1. **Raised right ventricular pressures**
pulmonary arterial hypertension
cor pulmonale
2. **valvular disease**
tricuspid regurgitation
tricuspid stenosis
Ebstein anomaly
3. Atrial septal defect (ASD)
4. atrial fibrillation (AF)
5. dilated cardiomyopathy



LA enlargement

(i). Widening of carina(normal 45-75 degree)

(ii). Elevation of left bronchus

(iii). Straightening of left border

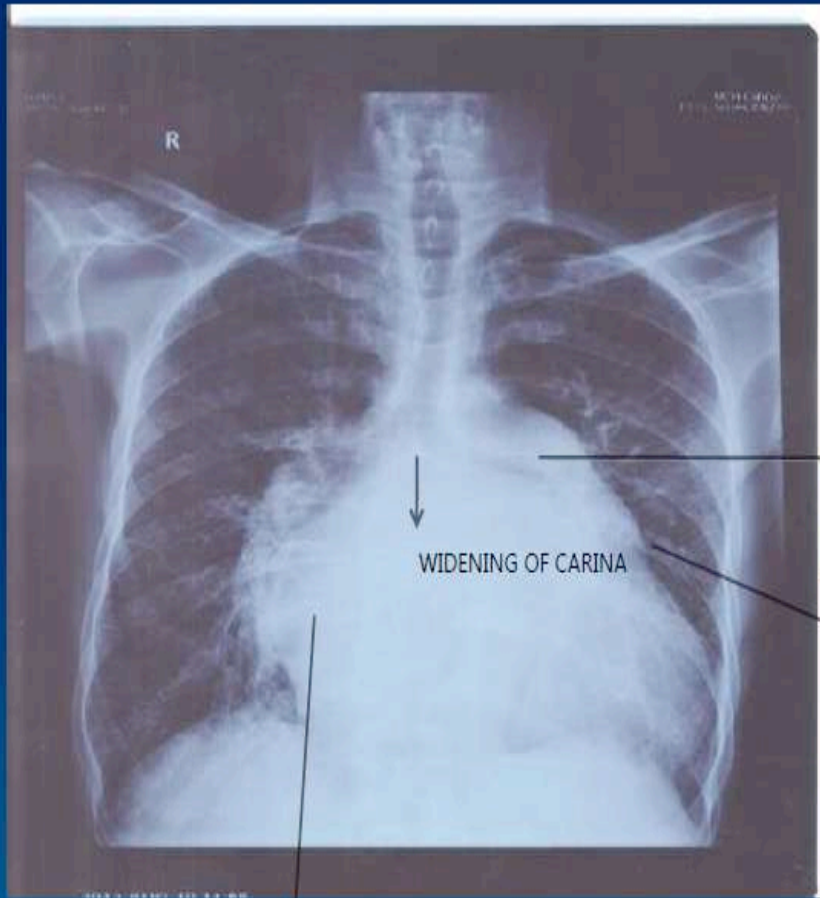
(iv). Double atrial shadow(shadow within shadow)

Grade 1 –double cardiac contour

Grade 2 - LA touches RA border

Grade 3 – LA overshoots the Rt. Cardiac border

(v). Displaces the descending aorta to the left and esophagus to right seen in barium swallow

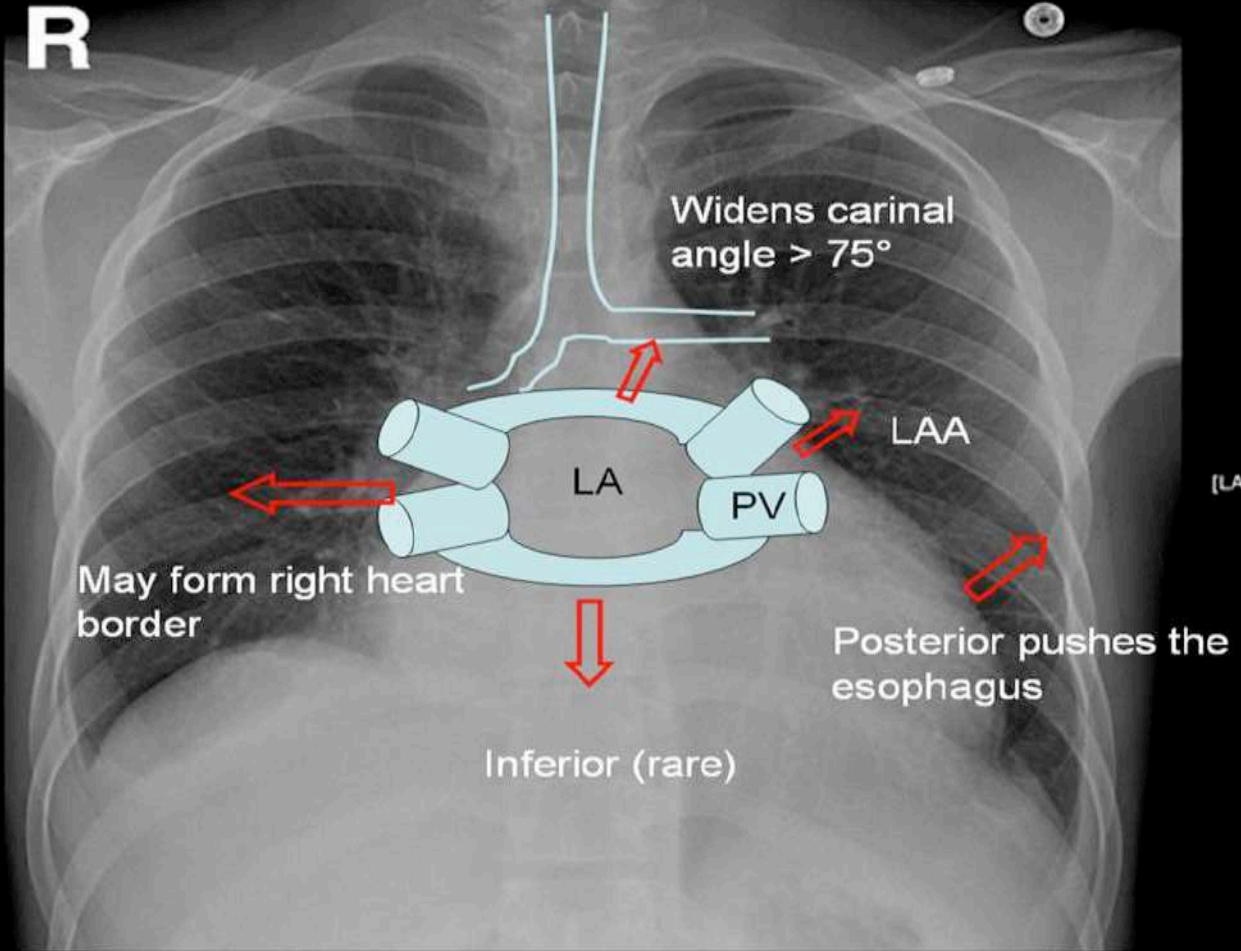


DOUBLE ATRIAL SHADOW

WIDENING OF CARINA

ELEVATION OF LEFT BRONCHUS

Left atrial appendage enlargement



Widens carinal angle $> 75^\circ$

LAA

LA

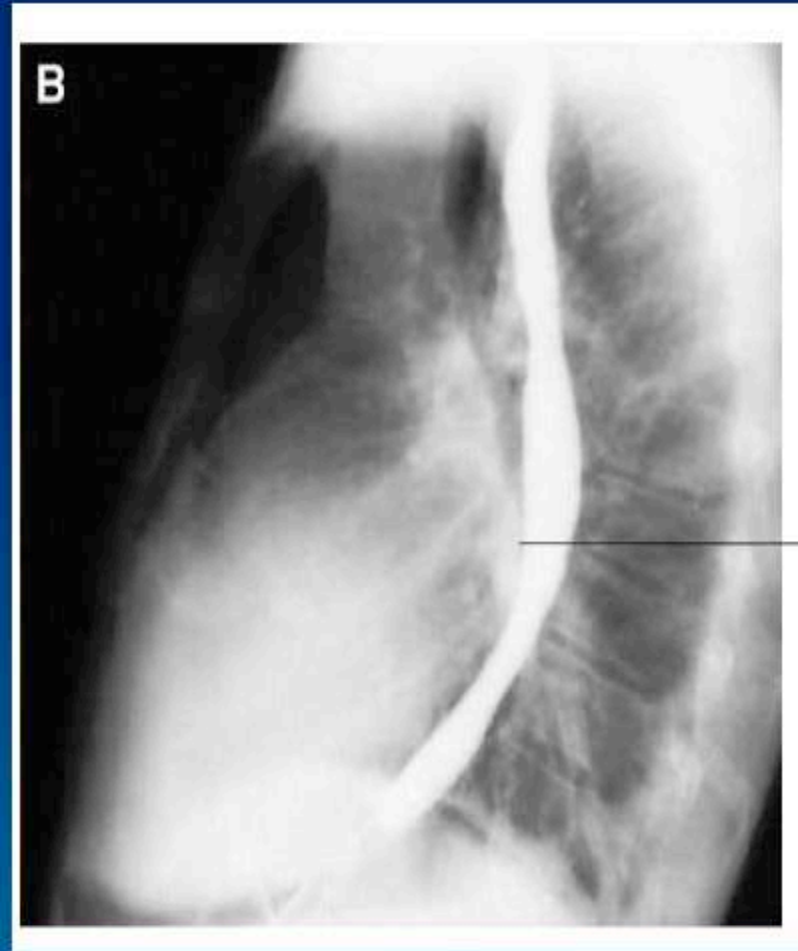
PV

May form right heart border

Posterior pushes the esophagus

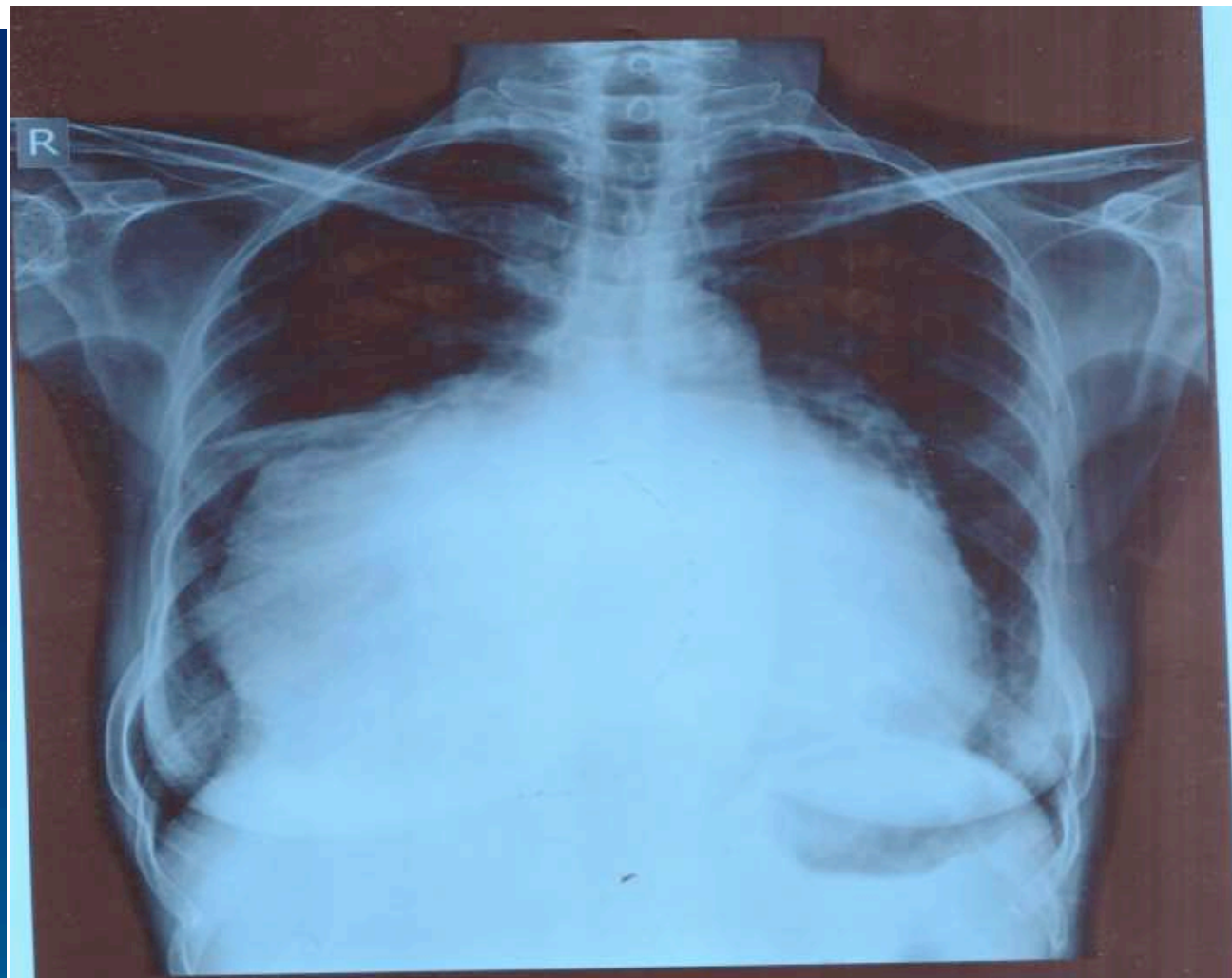Inferior (rare)

Modes of left atrial enlargement



LA pushing the
Esophagus posterior

LATERAL VIEW-LA ENLARGEMENT



Aneurysmal LA – When La enlarges to left and right and approaches within an inch of lateral chest wall

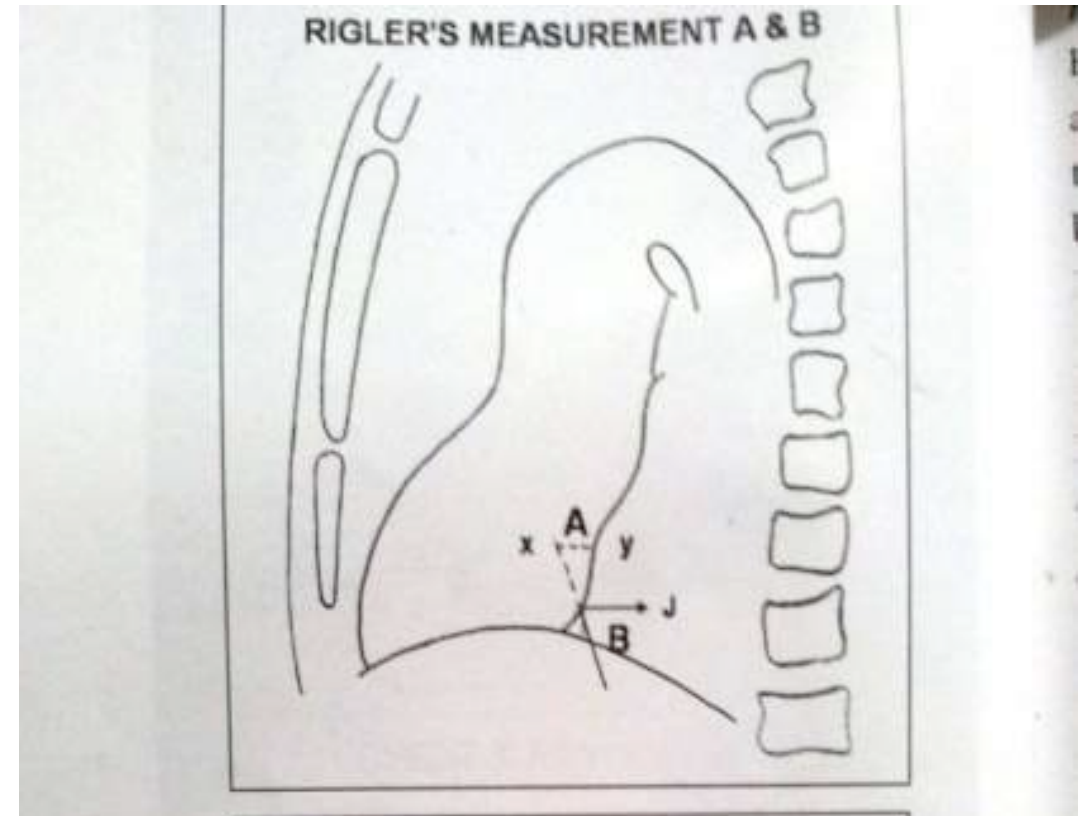
RIGLER'S MEASUREMENT

1. Rigler's A & B used to differentiate left ventricular and right ventricular enlargement
2. Possible only when IVC shadow is present
3. Jn. Of IVC with Lt. Atrium – J point
4. Rigler's A- from J point along line of IVC draw a line of 2 cm above and mark the point X.
5. Draw a horizontal line from pt. A to posterior Cardiac border and mark that pt. y
6. Distance between points x & y is Rigler's measurement A

NORMAL < 17 mm

Rigler's B- from the pt. J drop a perpendicular line to the dome and this distance is Rigler's measurement B

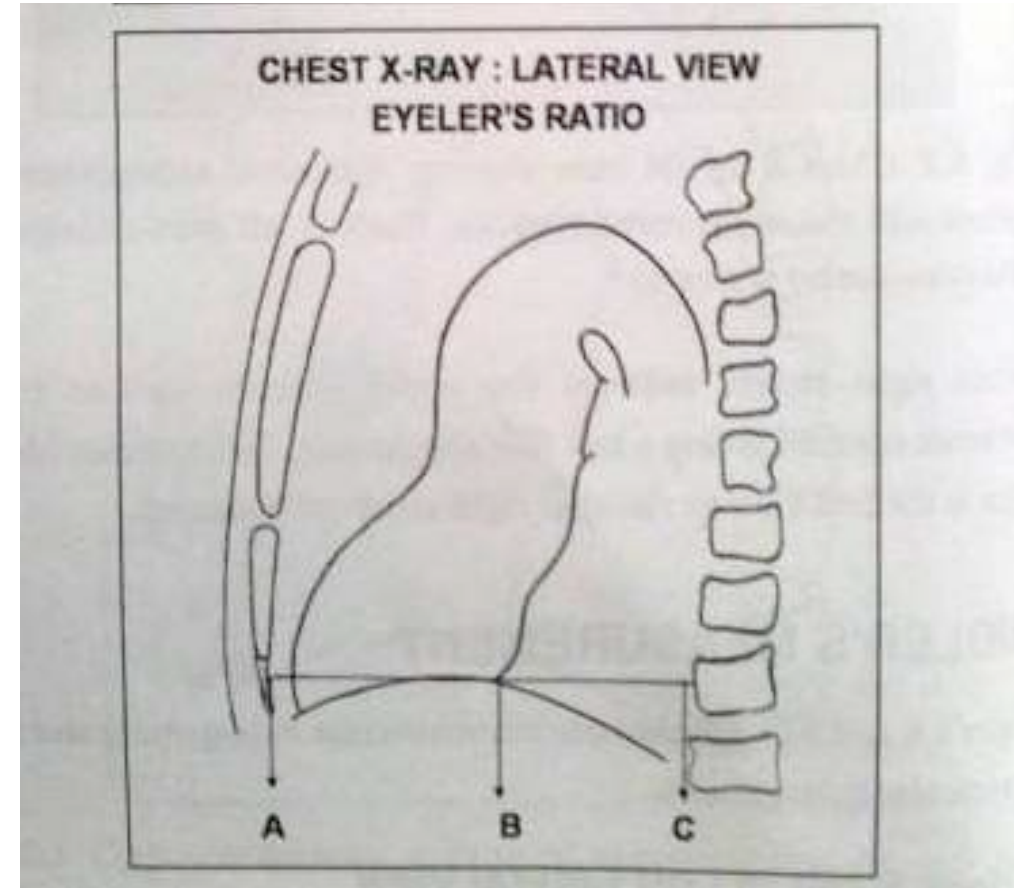
NORMAL > 7.5 mm



EYELER'S RATIO

1. To differentiate lt. & rt. Ventricular enlargement
2. Valid when IVC shadow is absent or cannot be visualised
3. Mark the point of jn. where postero inferior cardiac border meets the dome as B
4. From this point B draw a horizontal line to the posterior border of sternum-AB
5. From pt.B - draw another horizontal line posteriorly to the inner border of the rib-BC

Ratio of AB/BC is Eyeler's ratio < 0.42



RV ENLARGEMENT

(i). PA view

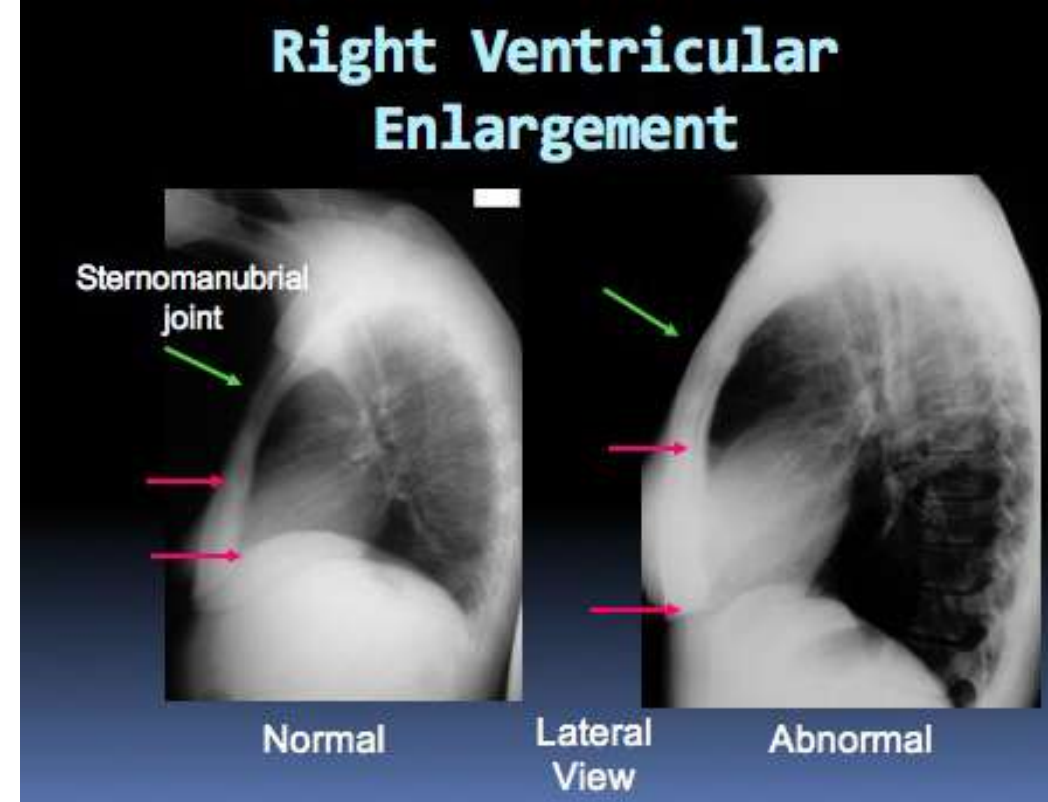
- Cardiophrenic angle is acute.
- Clockwise rotation of heart causes RV to form the middle portion of the left heart border.

(ii). RIGHT LATERAL VIEW

- Obliteration of retrosternal space

(iii). LEFT LATERAL VIEW

- Rigler's measurement will be 17mm or less
- Rigler's measurement will be 7.5mm or more
- Eyeler's ratio is 0.42 or less



LEFT VENTRICULAR ENLARGEMENT

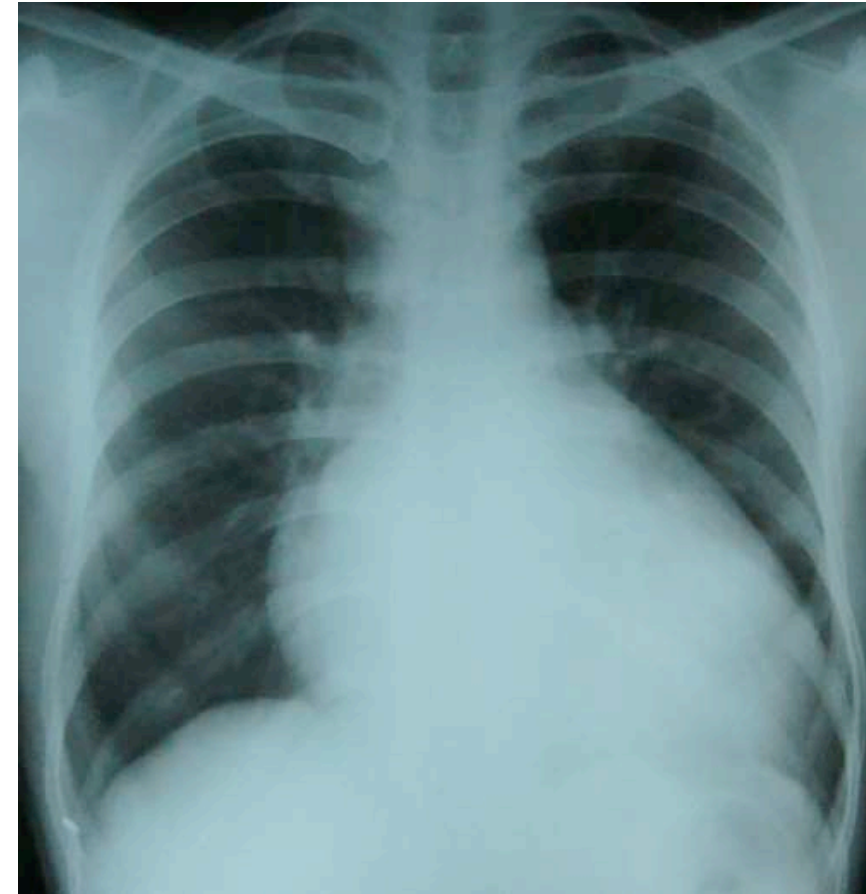
(i). PA view

(a) Left cardiac border gets enlarged and becomes more convex resulting in cardiomegaly

(b) Lt. cardiac border dips into lt. dome of diaphragm

(c) rounded apical segment

(d) cardiophrenic angle is obtuse



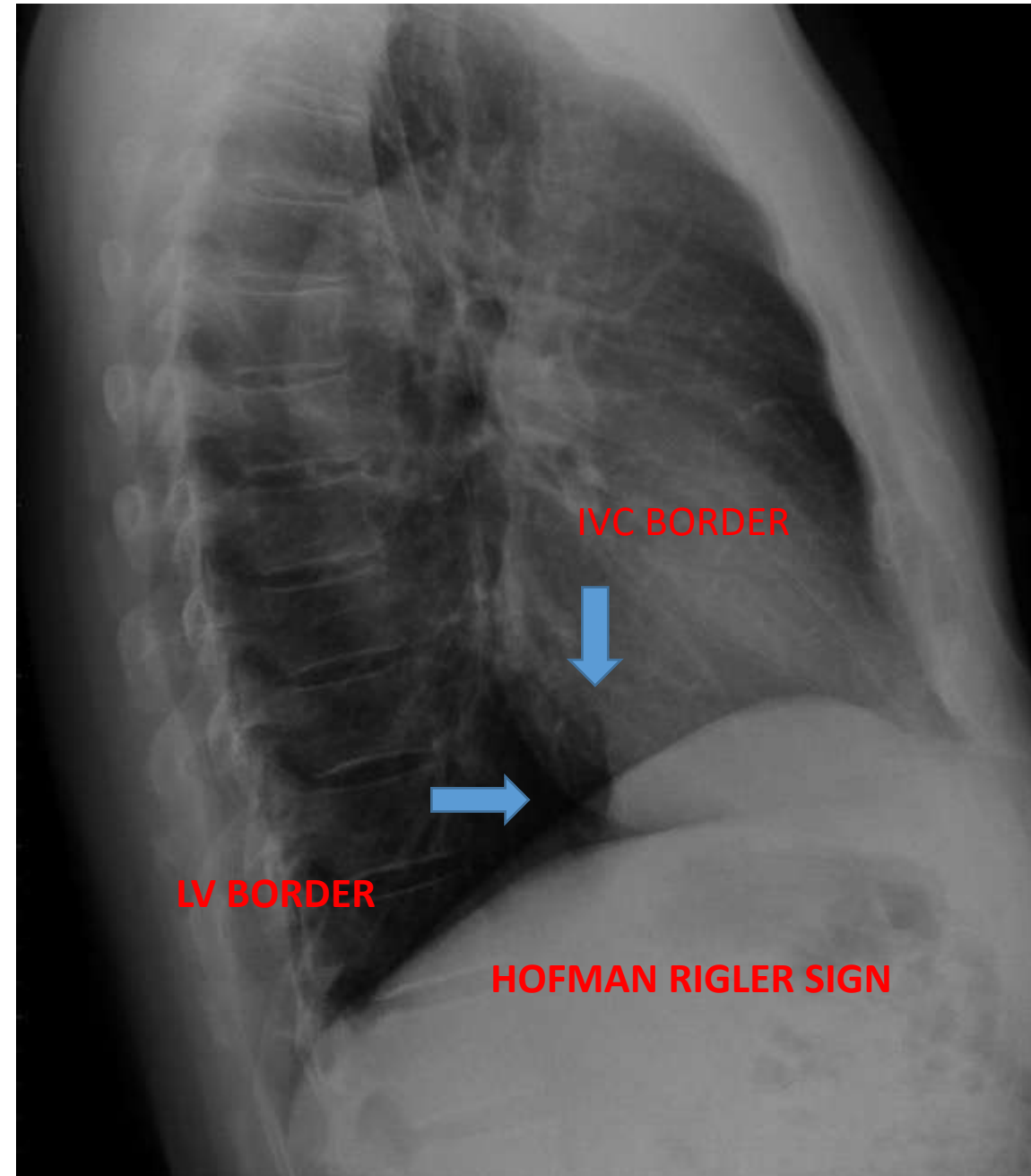
(ii). **Lateral view**

(a) Left ventricle enlarges inferiorly and posteriorly

(b) Rigler's measurement A is >17 mm

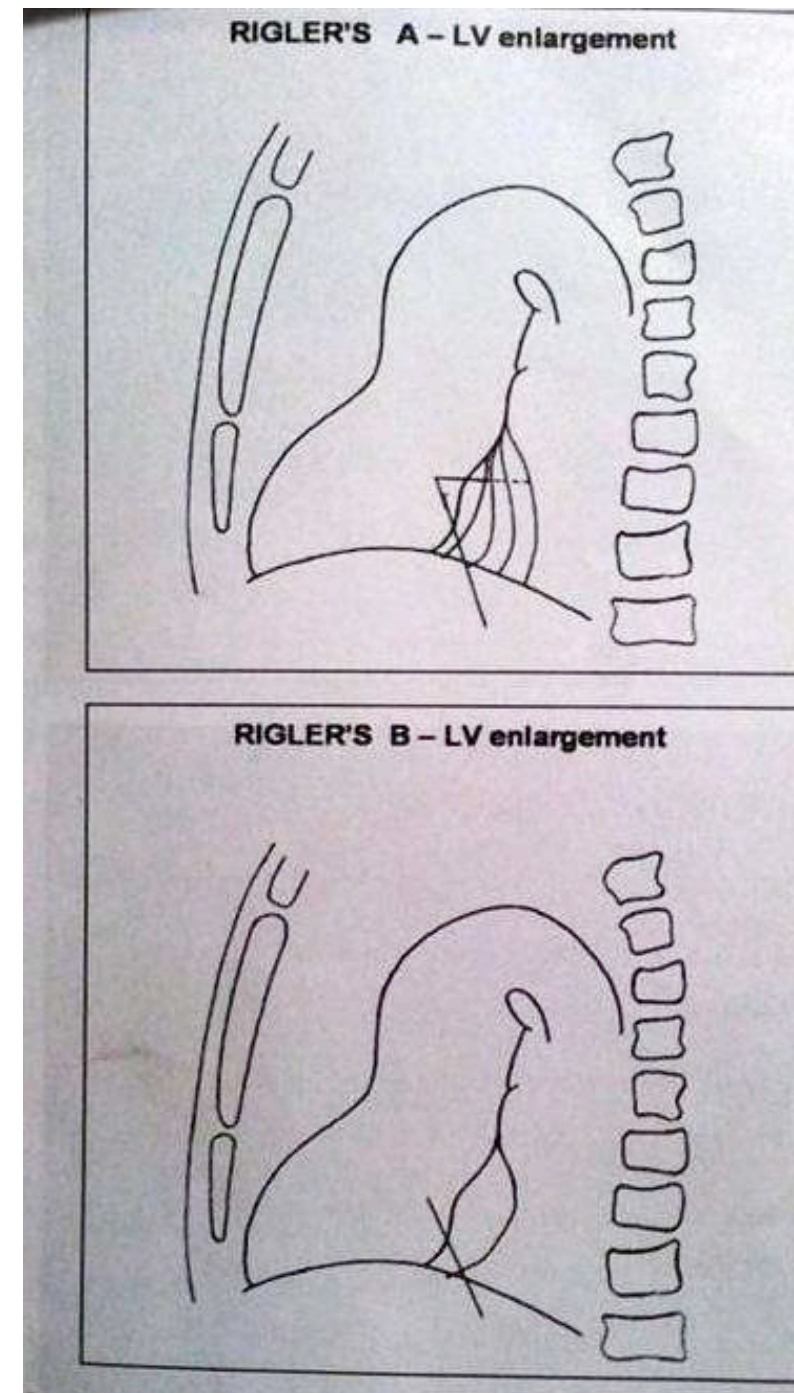
(c) Rigler's measurement B is < 7.5 mm

(d) Eyeler's ratio becomes > 0.42



When LV enlarges,
Posterior cardiac border gets displaced
posteriorly & IVC shadow gets included in
cardiac shadow, without getting displaced
posteriorly

Rigler's measurement A >17 mm in Lt.
ventricular enlargement



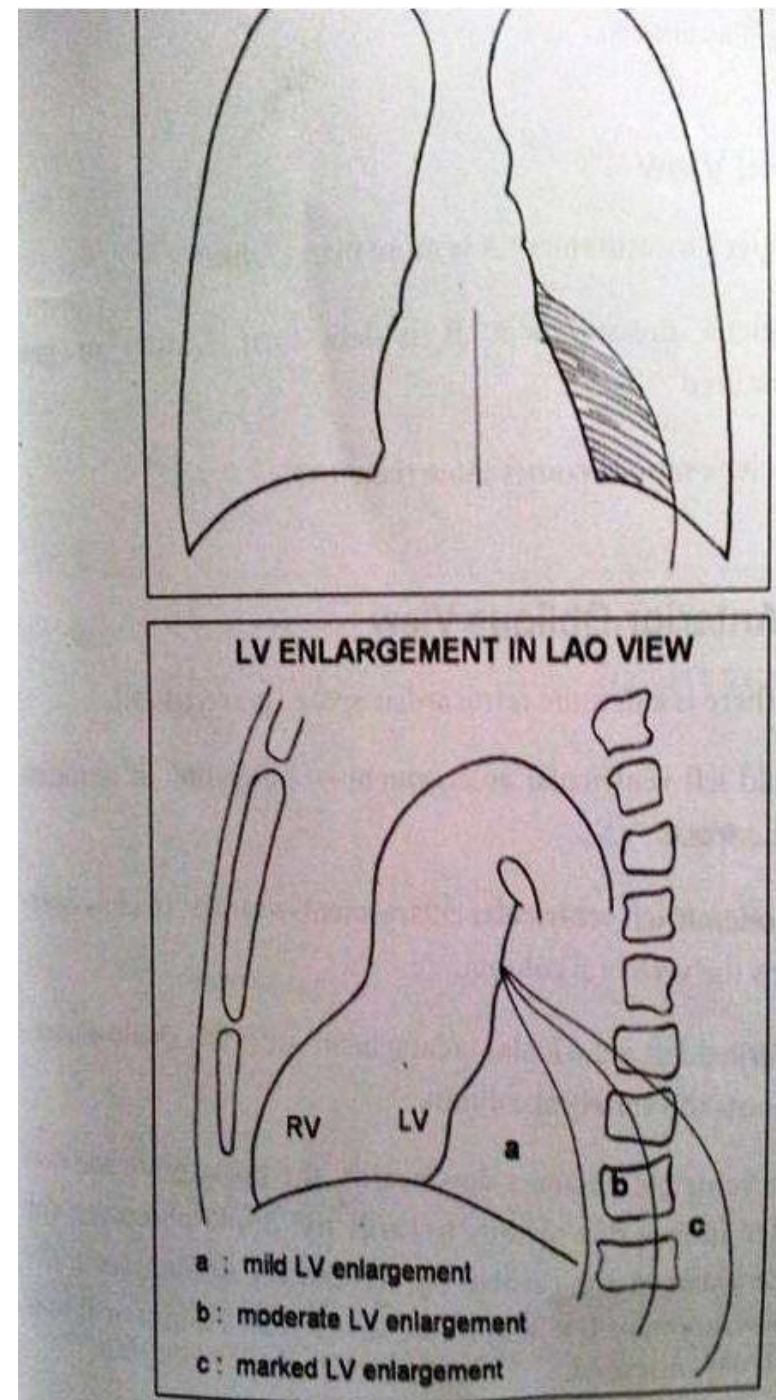
- **LA Oblique view**

- There is a retrocardiac space(prevertebral)

(a)Mild Lt. Ventricular enlargement-obliteration of retrocardiac space

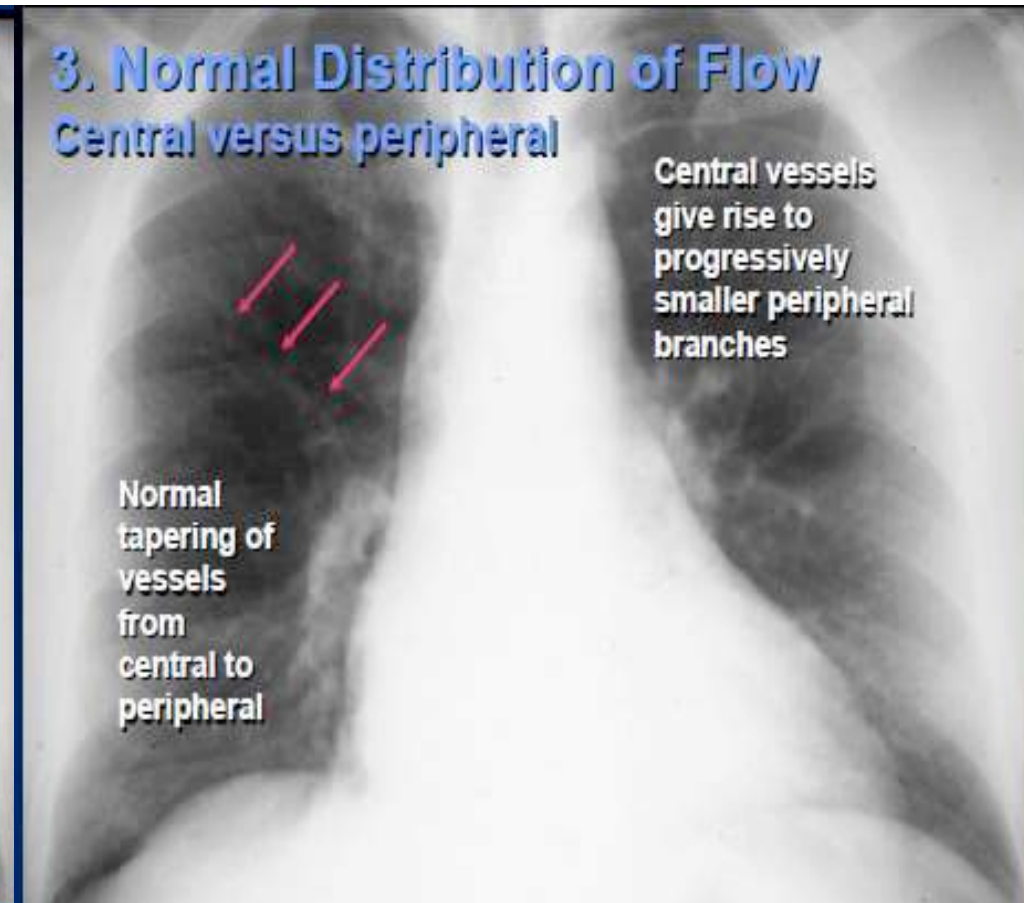
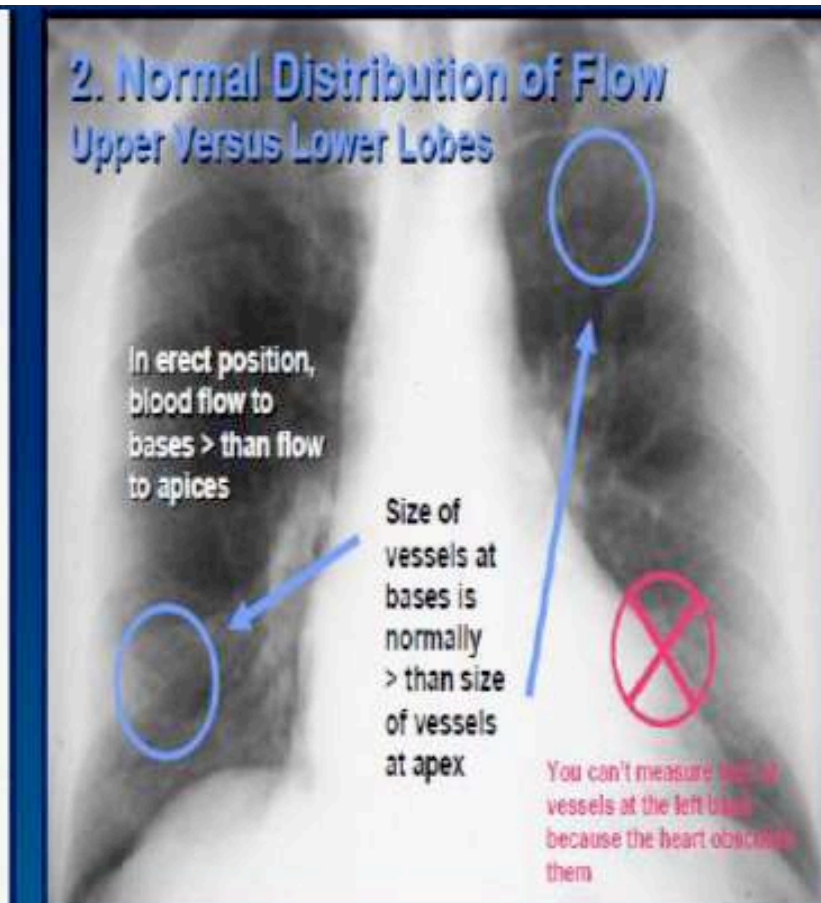
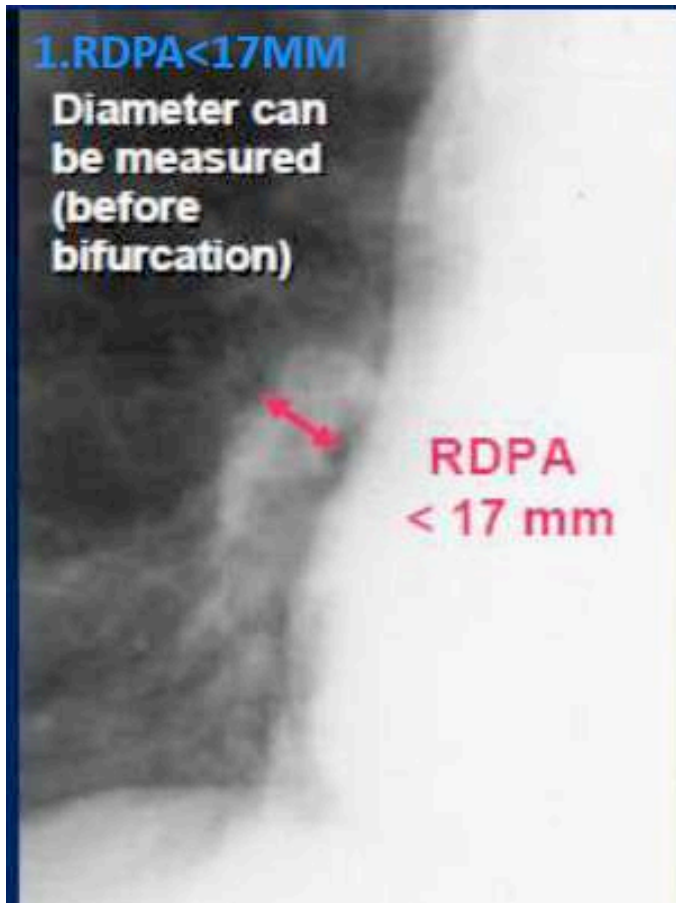
(b) mod. Lt.ventricular enlargement-cardiac shadow overlaps vertebral column

(c)Marked Lt.ventricular enlargement-cardiac shadow overshoots vertebral column



Assessment of PVH and PAH

NORMAL PULMONARY CIRCULATION – 3 FEATURES



PULMONARY VENOUS HYPERTENSION

- LARRY ELLIOT'S CLASSIFICATION OF PVH

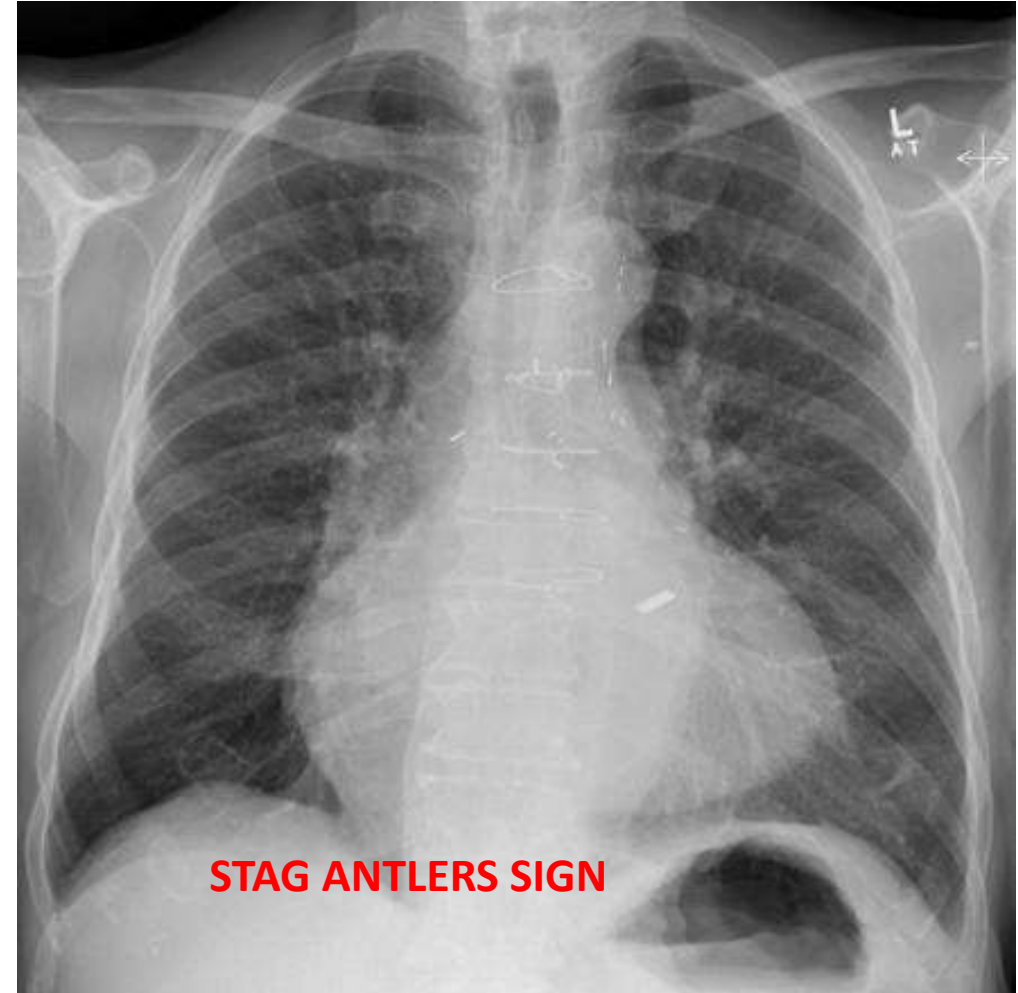RADIOGRAPHIC GRADE OF PVH	ACUTE DISEASE PCWP	CHRONIC DISEASE PCWP
1	13-17 MMHG	13-17 MMHG
2	18-25 MMHG	18-30 MMHG
3	>25 MMHG	>30 MMHG
4	HEMOSIDEROSIS AND OSSIFICATION	LONG STANDING PVH

GRADE 0 -PCWP< 12 MM HG

- Upper lobe pulmonary veins are less prominent than lower lobe veins

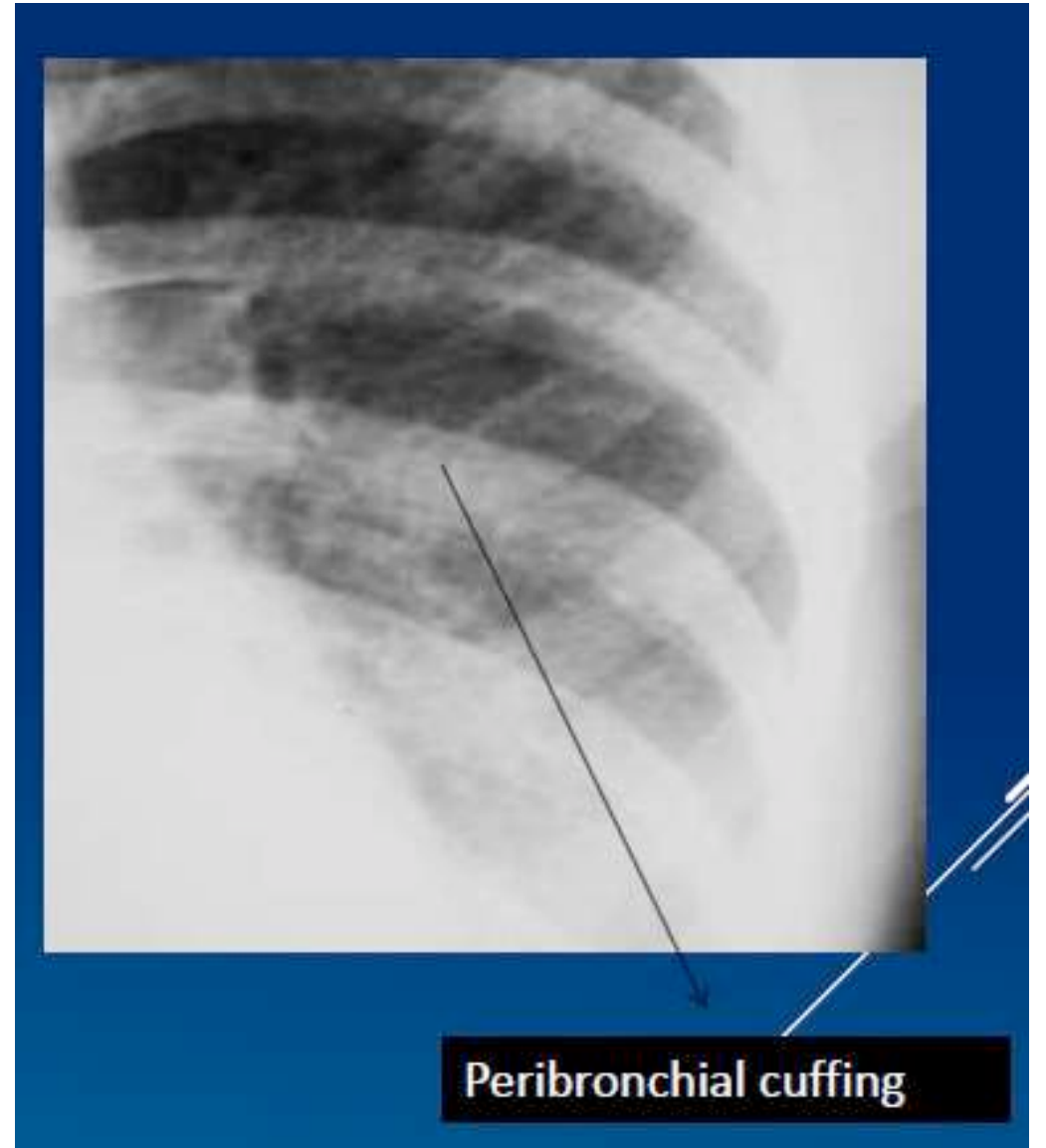
GRADE 1- PCWP 13-17MMHG

- Redistribution of blood flow with cephalization'
- ANTLER SIGN'
 - 1) increased resistance to flow due to interstitial edema
 - 2) alveolar hypoxia in lower lobes causes reflex vasoconstriction
 - 3) vasoconstriction of the arterioles due to LA or pulmonary vein reflex



GRADE 2- PCWP 18-25mm hg

- Interstitial edema
- Peribronchial cuffing
- Kerley A,B,C lines
- Interlobular effusion
- Pleural effusion
- Hilar haze
- Peribronchial

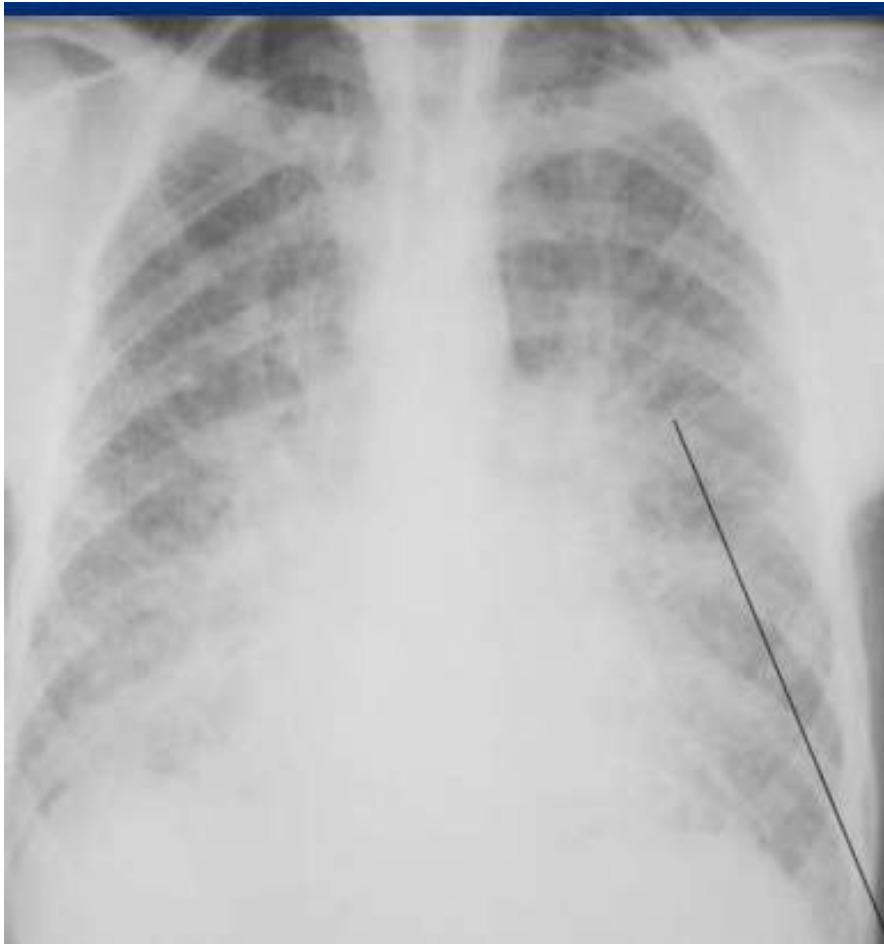

KERLEY A LINES

Distended lymphatic channels within edematous septa coursing from peripheral lymphatics to central hilar nodes

Towards the hilum

Less specific for Pulmonary venous hypertension



KERLEY B LINES

Horizontal lines

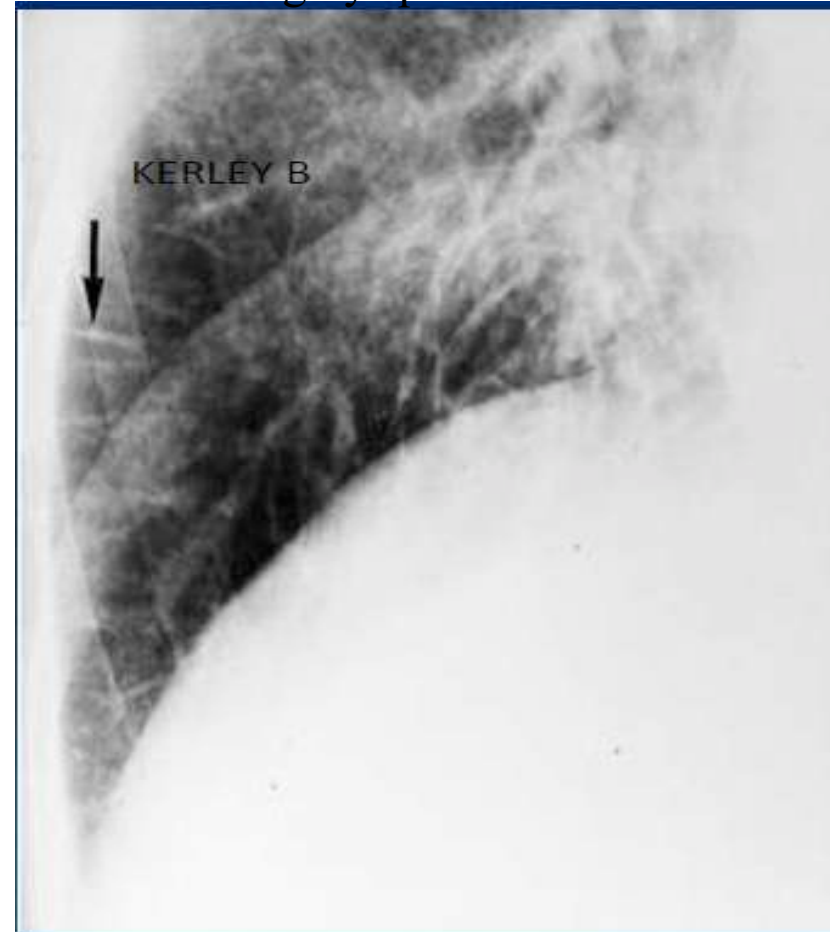1-3 mm thick

Perpendicular to pleural surface

Towards the costophrenic angle

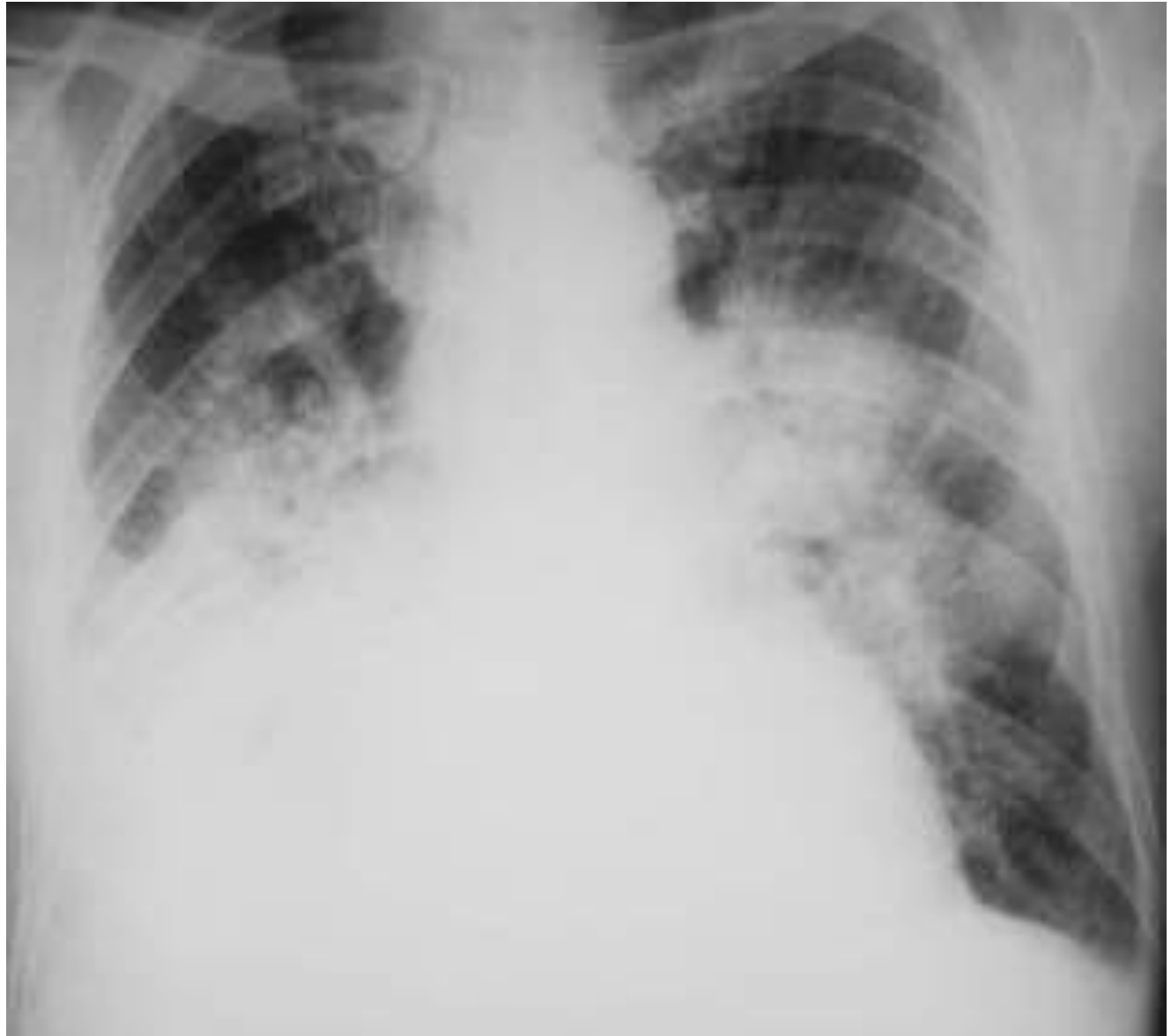Accumulation of fluid in interlobular septa and lymphatics

Highly specific for PVH



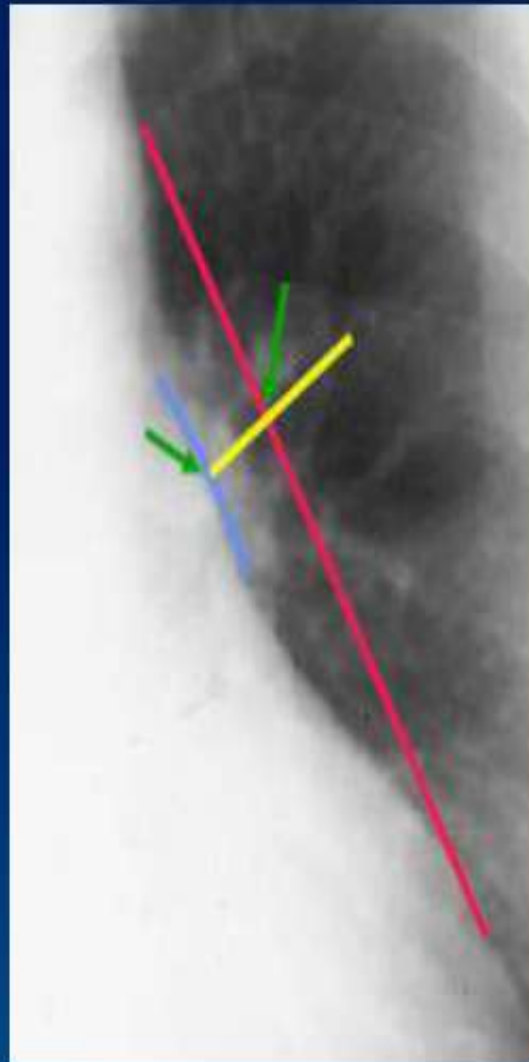
GRADE 3 – pcwp > 25mm hg

- Alveolar edema
- Bilateral diffuse patchy
- cotton wool opacities

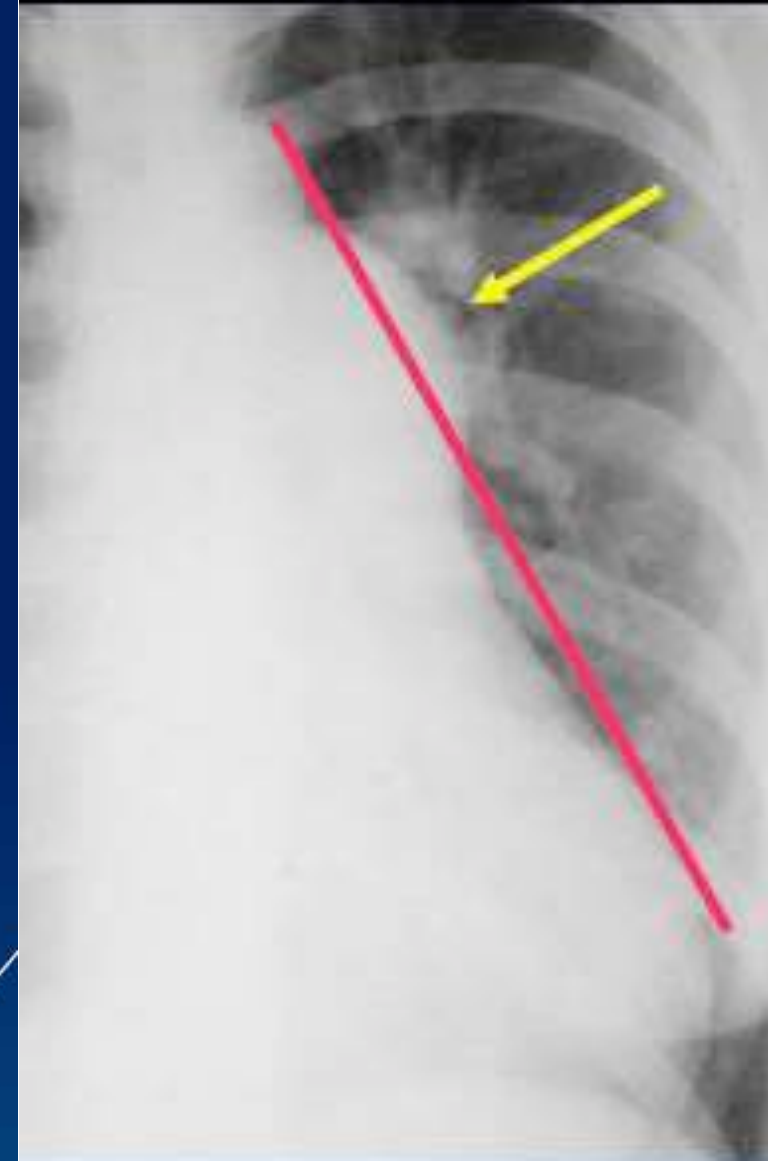

Pulmonary Artery hypertension

If we draw a tangent line from the apex of the left ventricle to the aortic knob (red line) and measure along a perpendicular to that tangent line (yellow line)



The distance between the tangent and the main pulmonary artery (between two small green arrows) falls in a range between 0 mm (touching the tangent line) to as much as 15 mm away from the tangent line

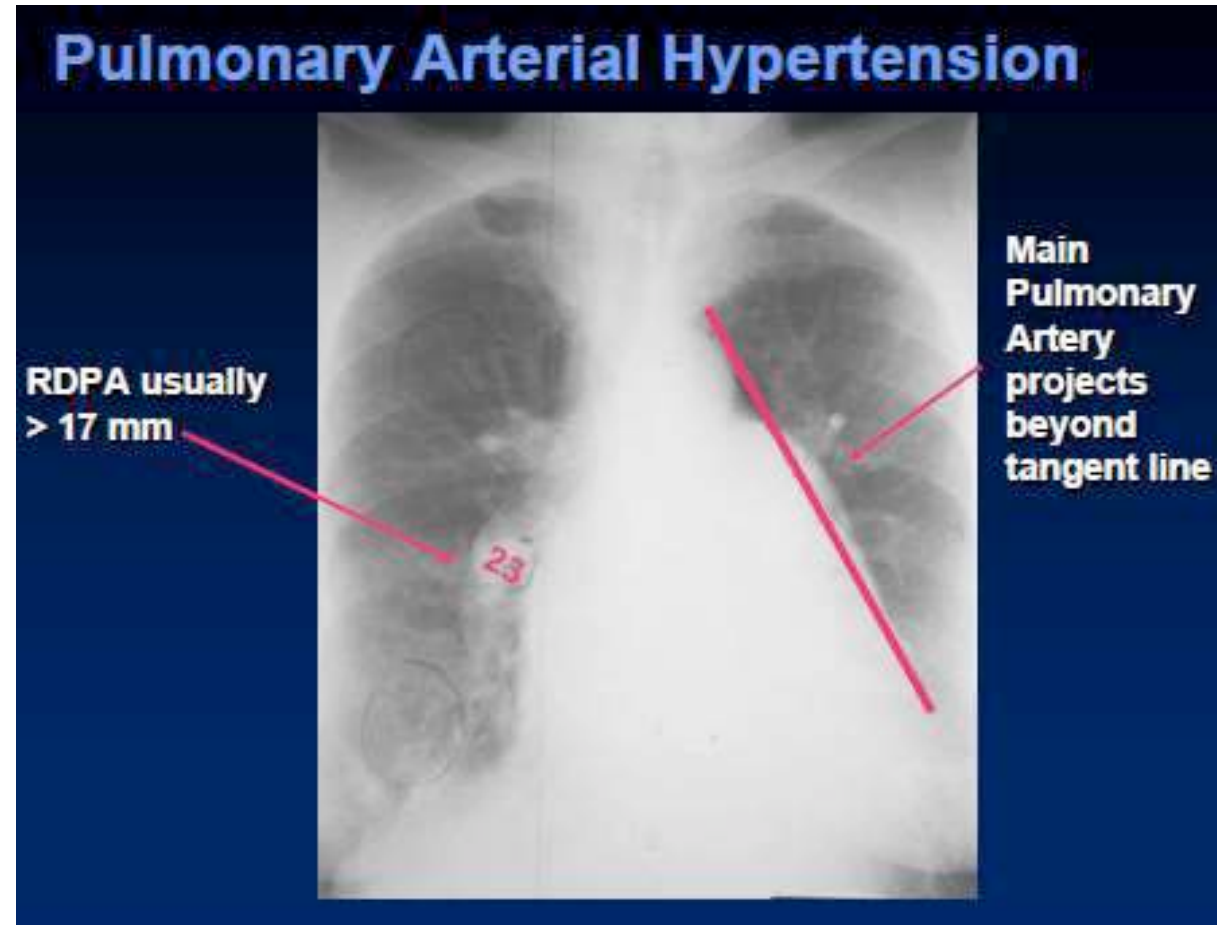


Criteria

- Prominent Main pulmonary Artery
- Right descending pulmonary artery
> **17 mm in males and > 16 mm in females.**
- Pruning of peripheral pulmonary artery.
- Reduced retro-sternal space on lateral views due to RV dilatation.

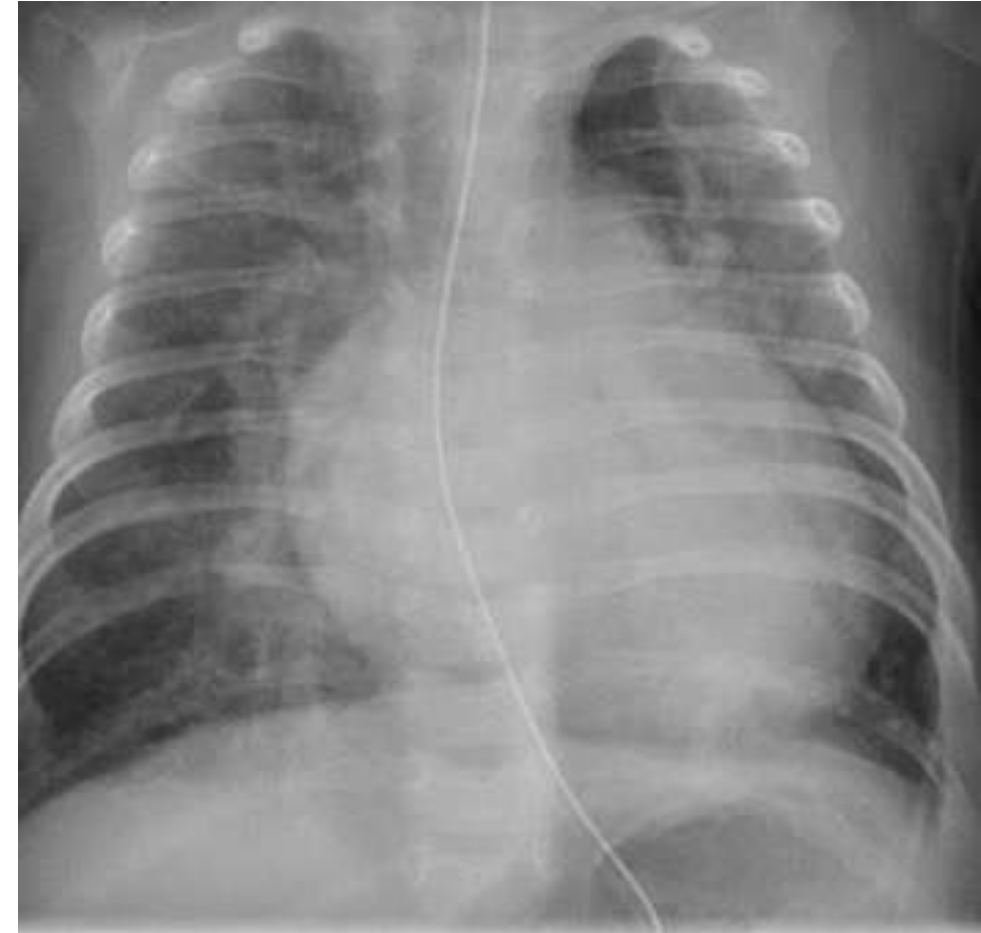Echo criteria for dilated pulmonary artery > 22 mm

CT criteria for dilated pulmonary artery > 26 mm



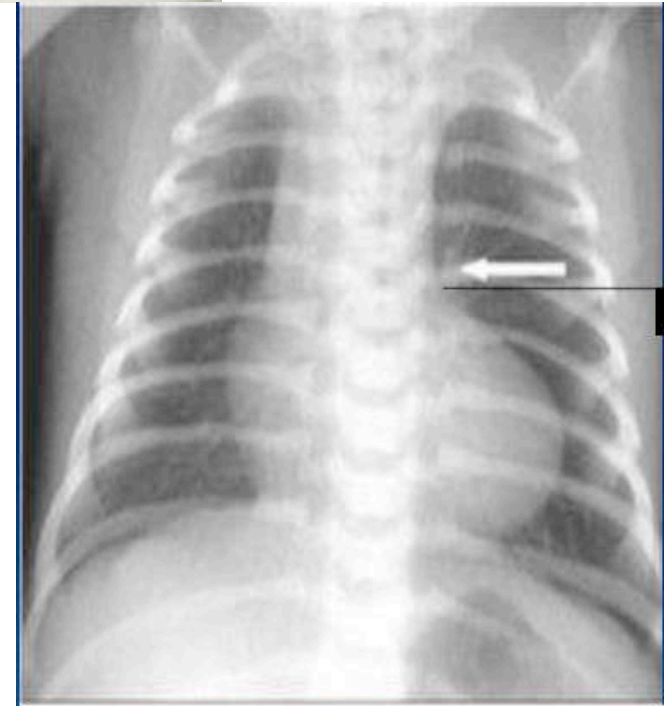
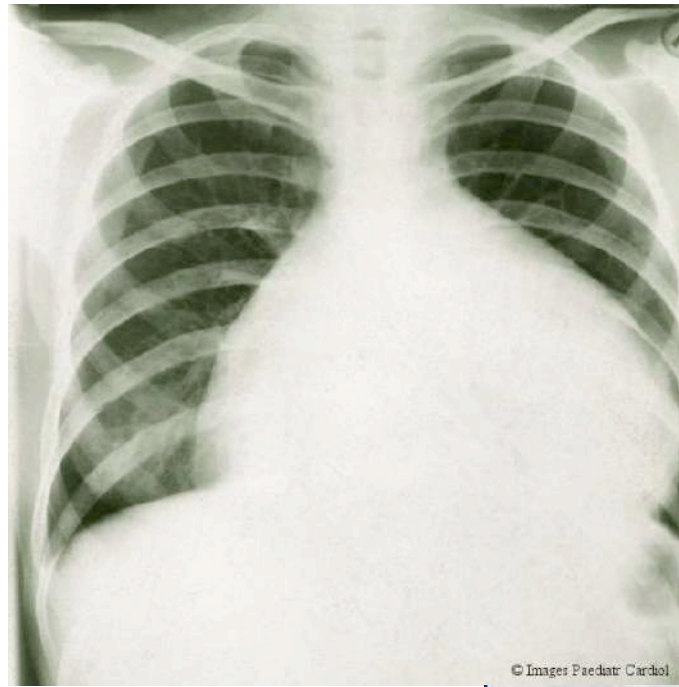
Pulmonary Plethora

- pulmonary vessels are dilated and tortuous extending farther into the peripheral one-thirds of the lungs
- diameter of a pulmonary artery is greater than the accompanying bronchus
- Right descending pulmonary artery to tracheal diameter Ratio > 1
- End-on's > 3 in one lung field and >5 in both lung fields.



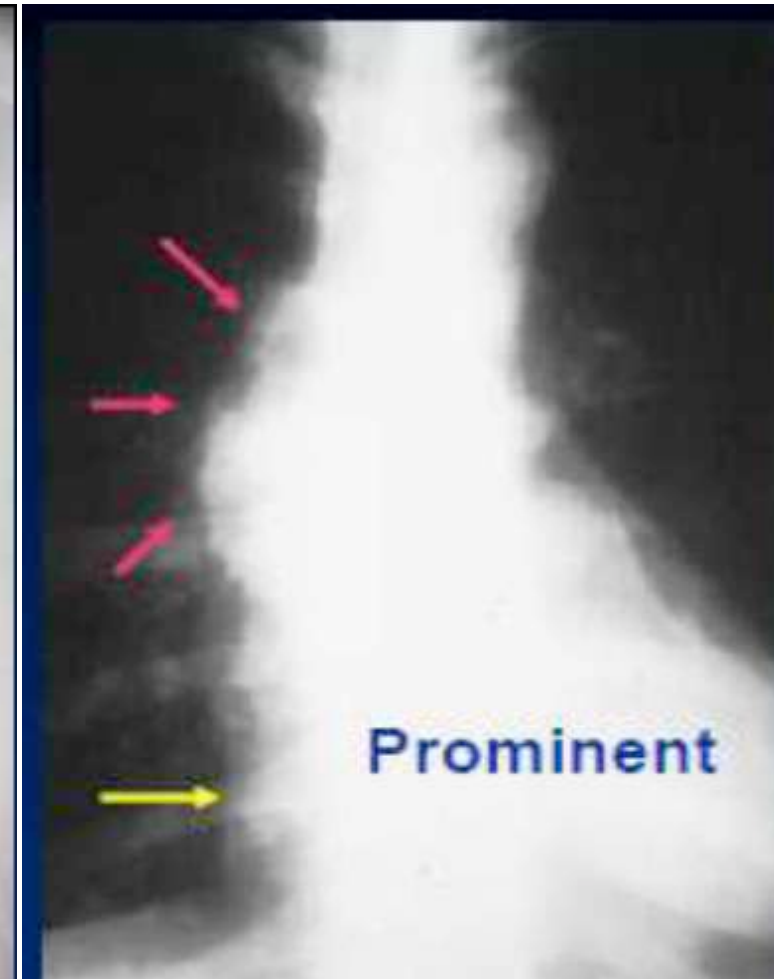
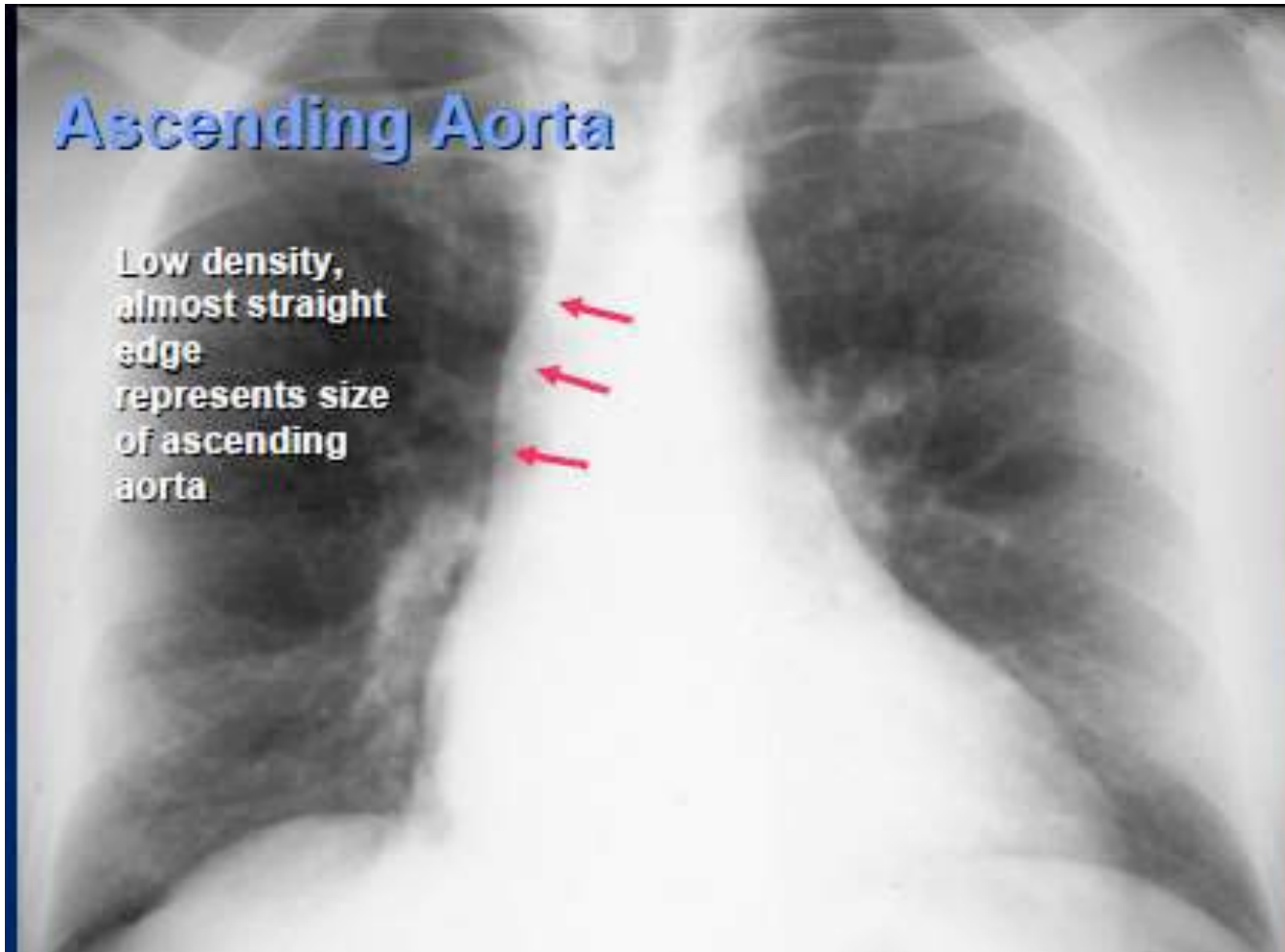
Pulmonary oligoemia

- Small pulmonary artery
- Empty pulmonary bay
- Pulmonary vessels small
- Lung hyper translucent
- Lateral view shows diminution of hilar vessels

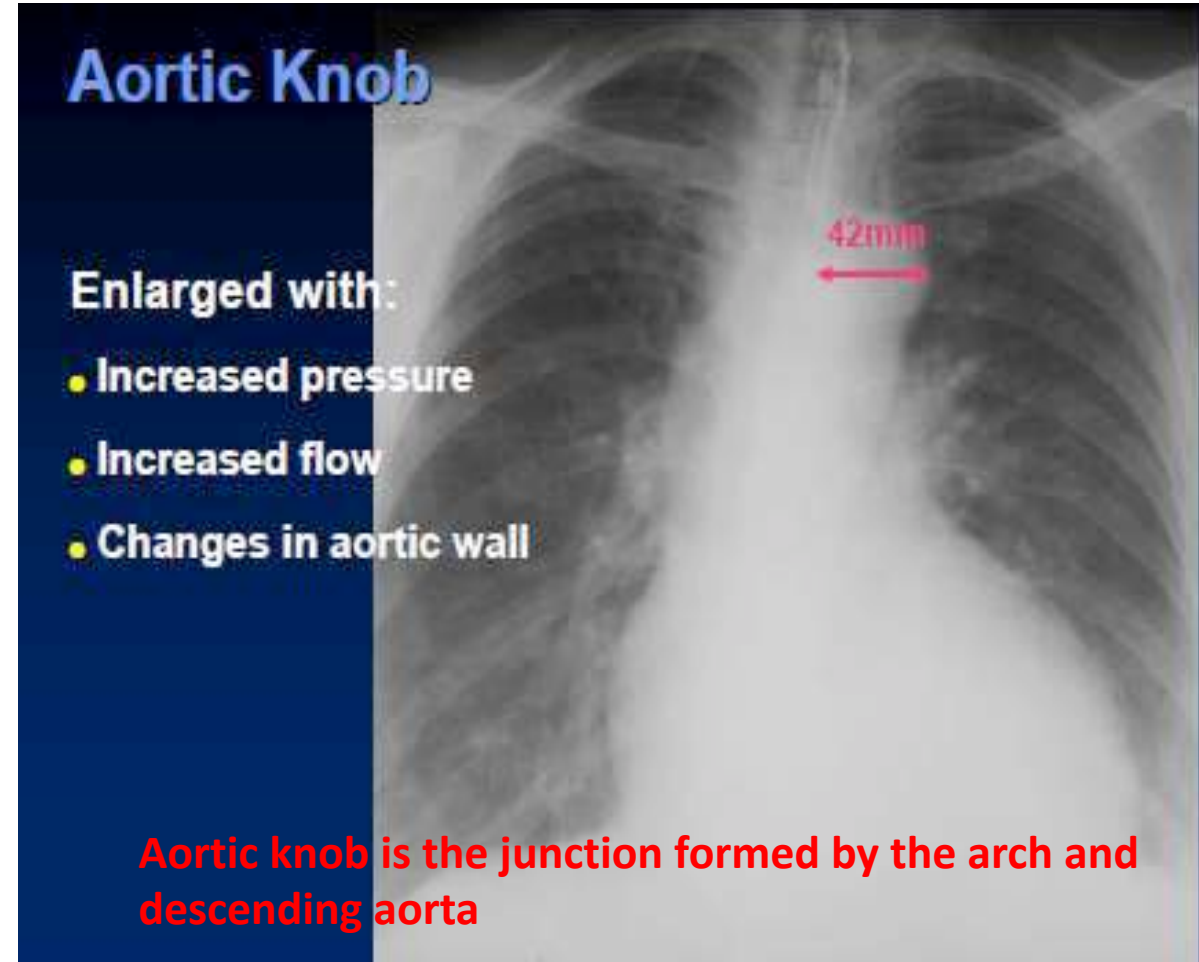
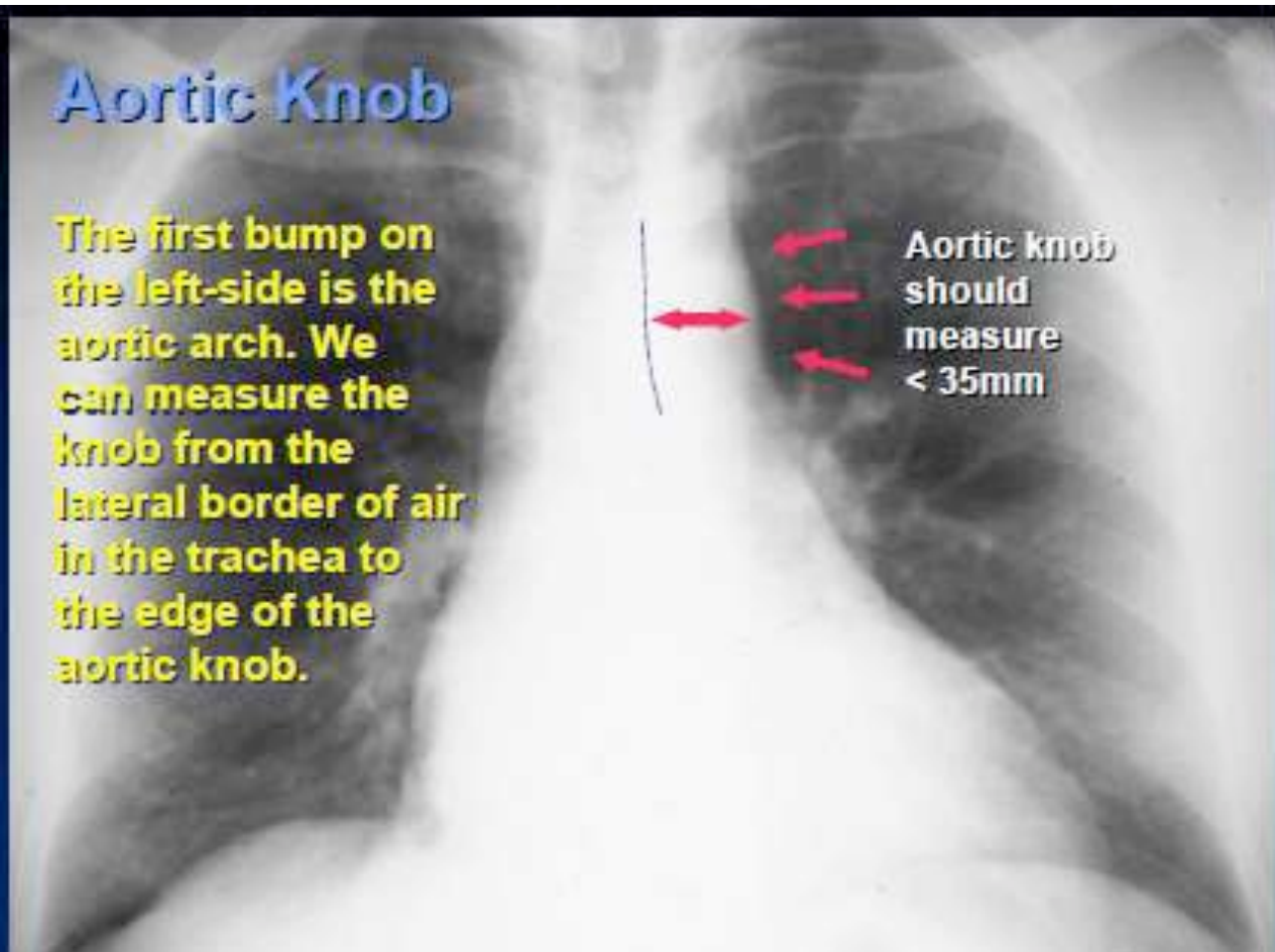


Empty pulmonary bay

Enlargement of Asc Aorta



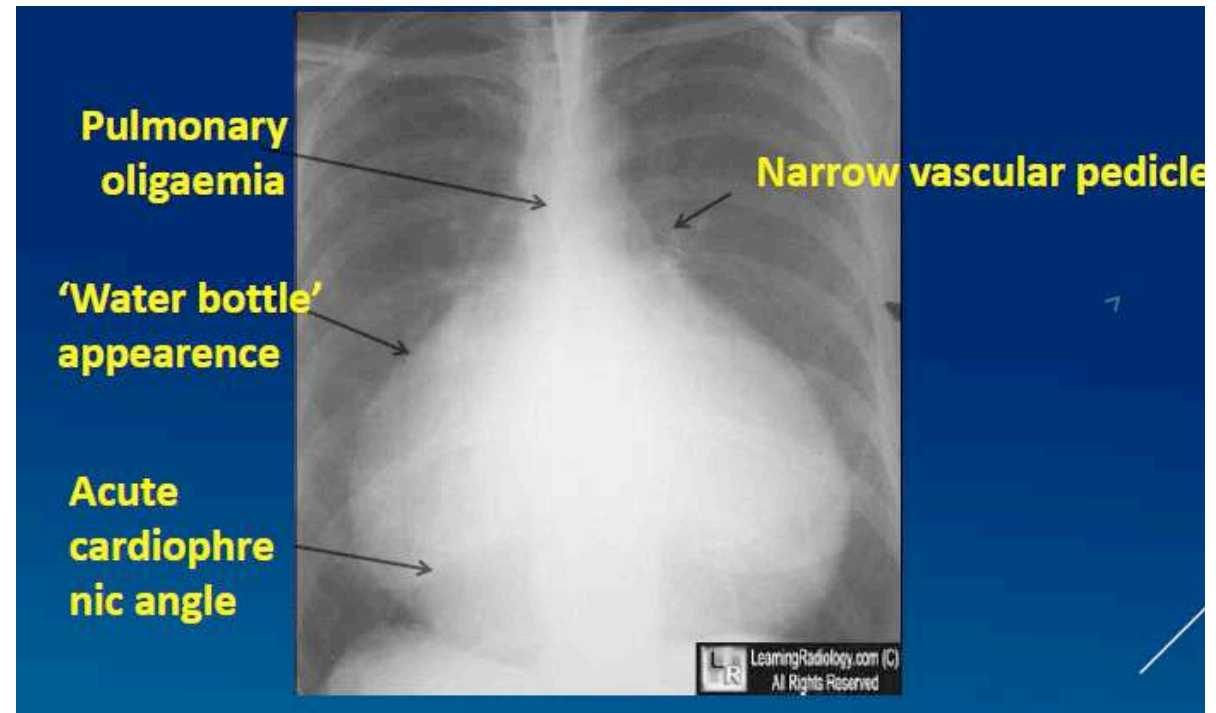
Enlargement of Aortic knob



Chest X Ray in Common Diseases

PERICARDIAL EFFUSION

- Narrow vascular pedicle
- Cardiomegaly directly proportional to severity of pericardial effusion
- This shadow has a rounded, globular appearance with no particular chamber enlargement
- Cardiophrenic angle become more and more acute
- Oligaemic pulmonary vascular markings
- Marked change in cardiac silhouette in decubitus posture
- 'Epicardial fat pad sign'- anterior pericardial strip bordered by epicardial fat post. and mediastinal fat ant.>2mm



versus DCM

- Chambers can be identified
- Cardiophrenic angle is obtuse
- Increased pulmonary venous hypertension
- No change in cardiac silhouette in decubitus
- Vascular pedicle is dilated or normal

Differentials for massive cardiomegaly

1. Pericardial effusion
2. Dilated cardiomyopathy
3. Multivalvular heart ds(AR+MR)
4. Ebsteins anomaly

CONSTRICTIVE PERICARDITIS

Straightening of the right border

Pericardial thickening > 4 mm

Pericardial calcification (50% cases)

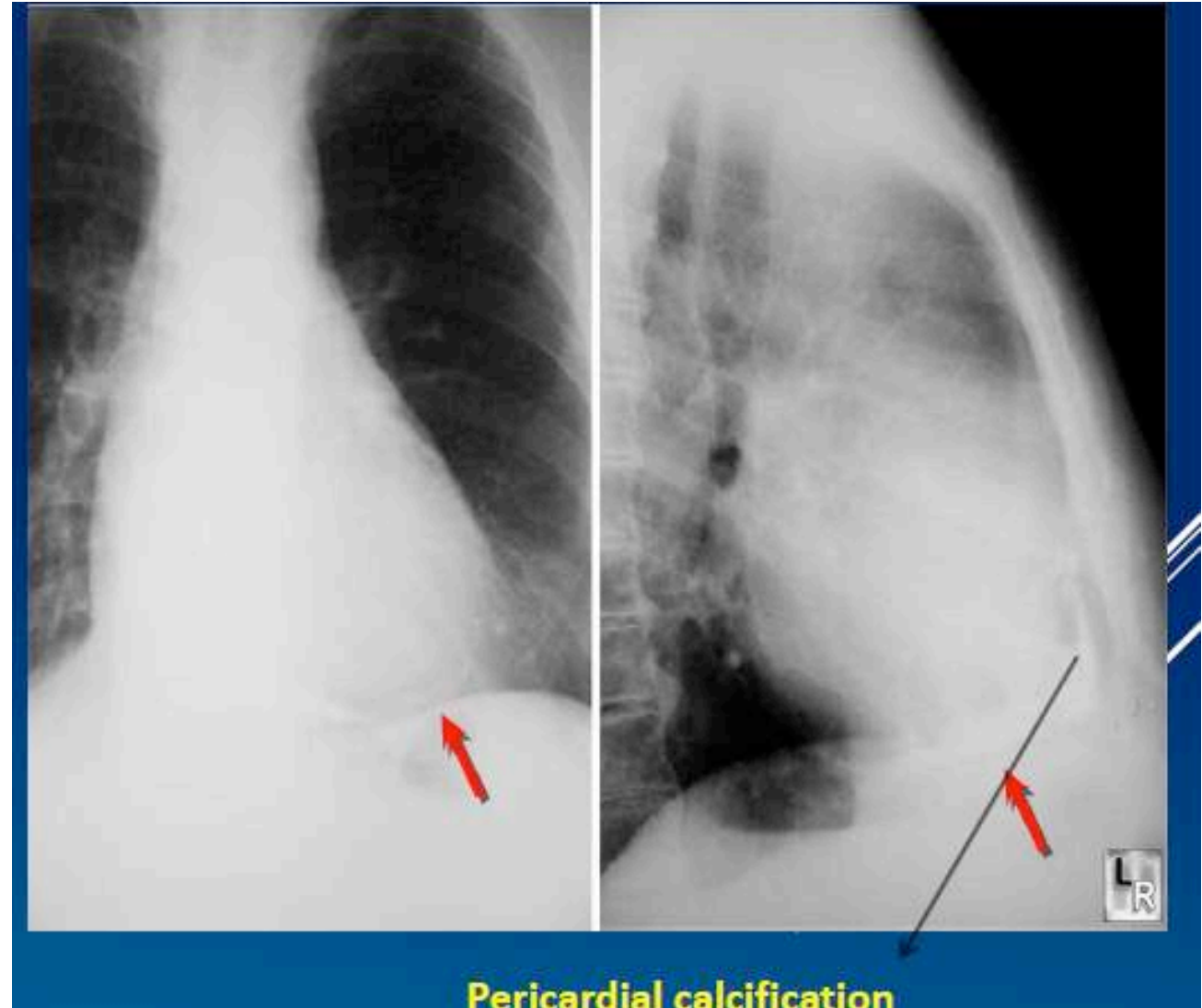
Dilatation of SVC and azygous vein

Important differential for Straightening of the right border is **Congenital absence of pericardium**

Focal bulge in area of main pulmonary artery

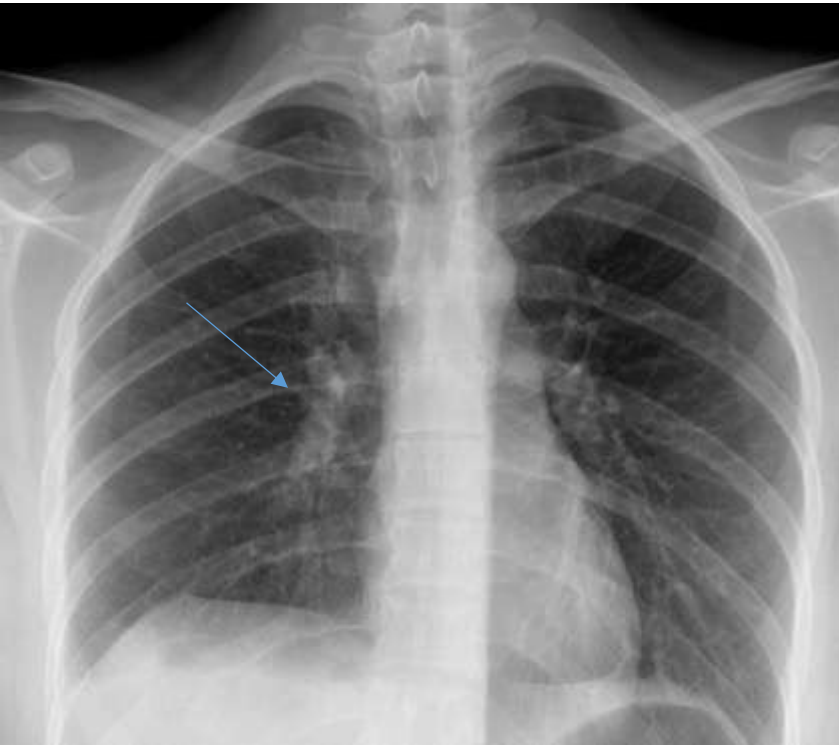Sharply marginated

Increased distance between sternum and heart due to absence of sterno pericardial ligament



Pericardial calcification

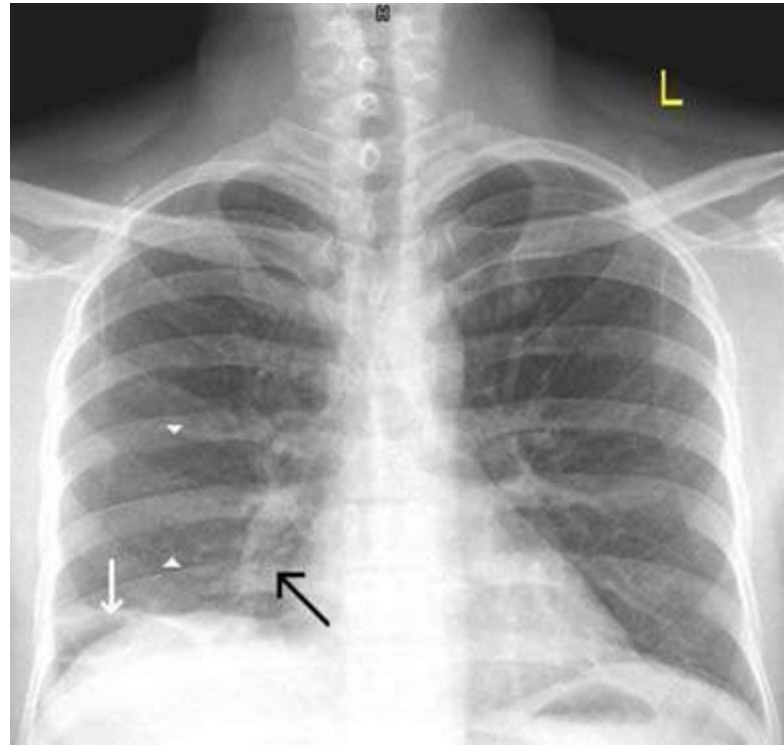
PULMONARY EMBOLISM



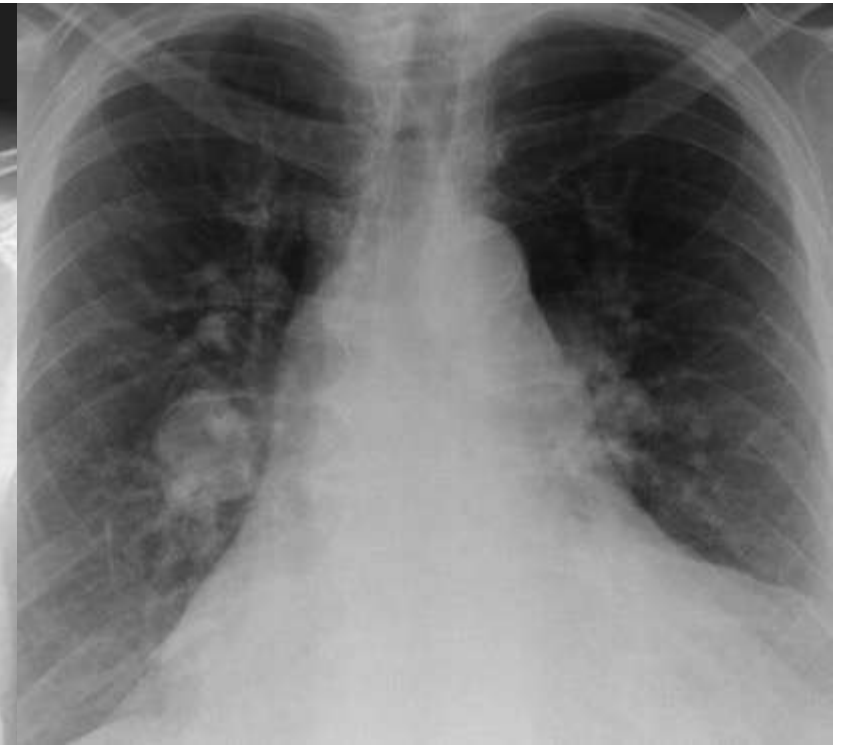Westermark sign - The sign is formed by dilatation of the pulmonary arteries proximal to the site of emboli followed by a sharp and demarcated collapse of the distal vasculature

Palla's sign- enlargement of the right descending pulmonary artery proximal to a cut off of the pulmonary artery due to acute pulmonary embolism.

Chang's sign – dilatation and abrupt change in calibre of the rt. Descending PA

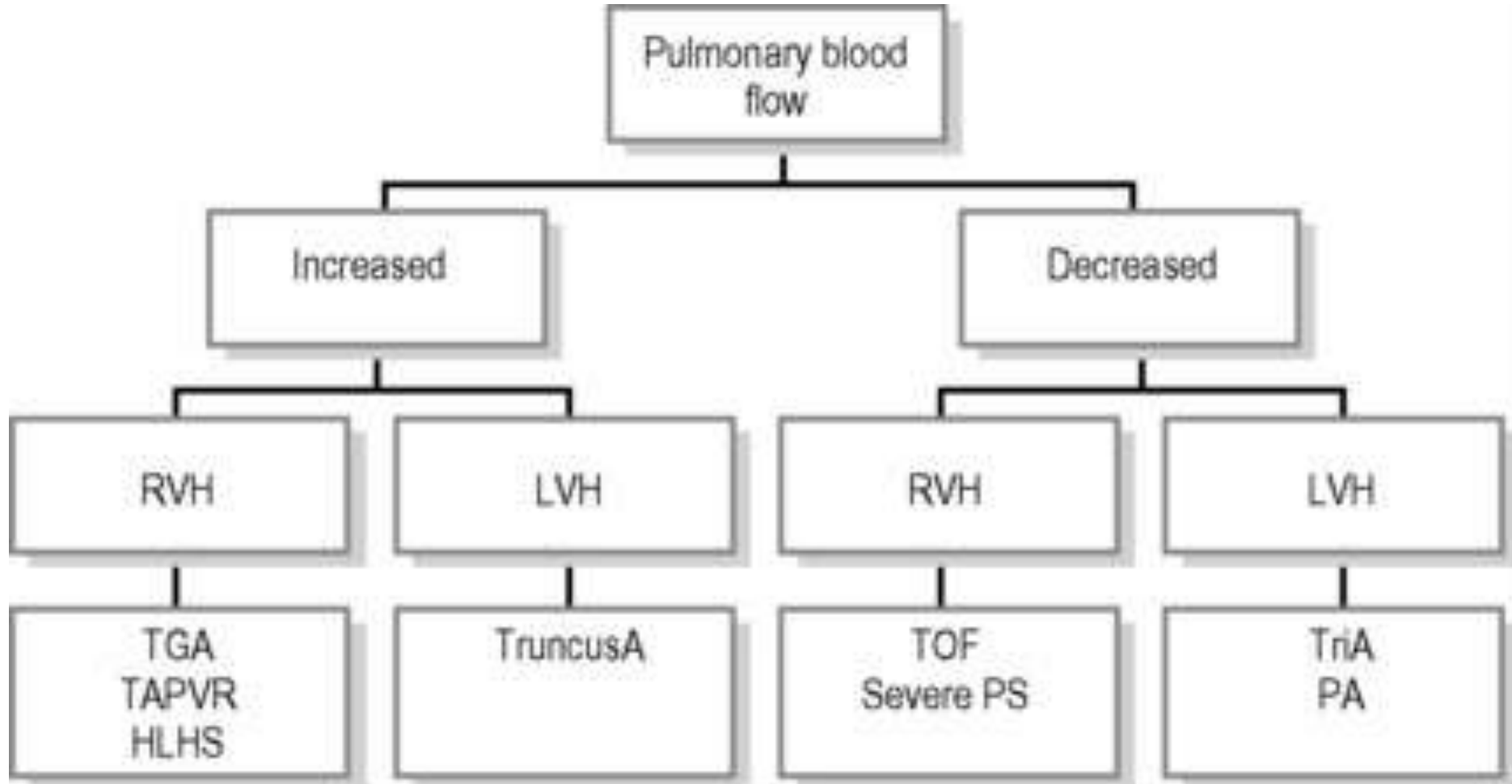


Hampton's hump - wedge-shaped opacity with a rounded convex apex directed towards the hilum



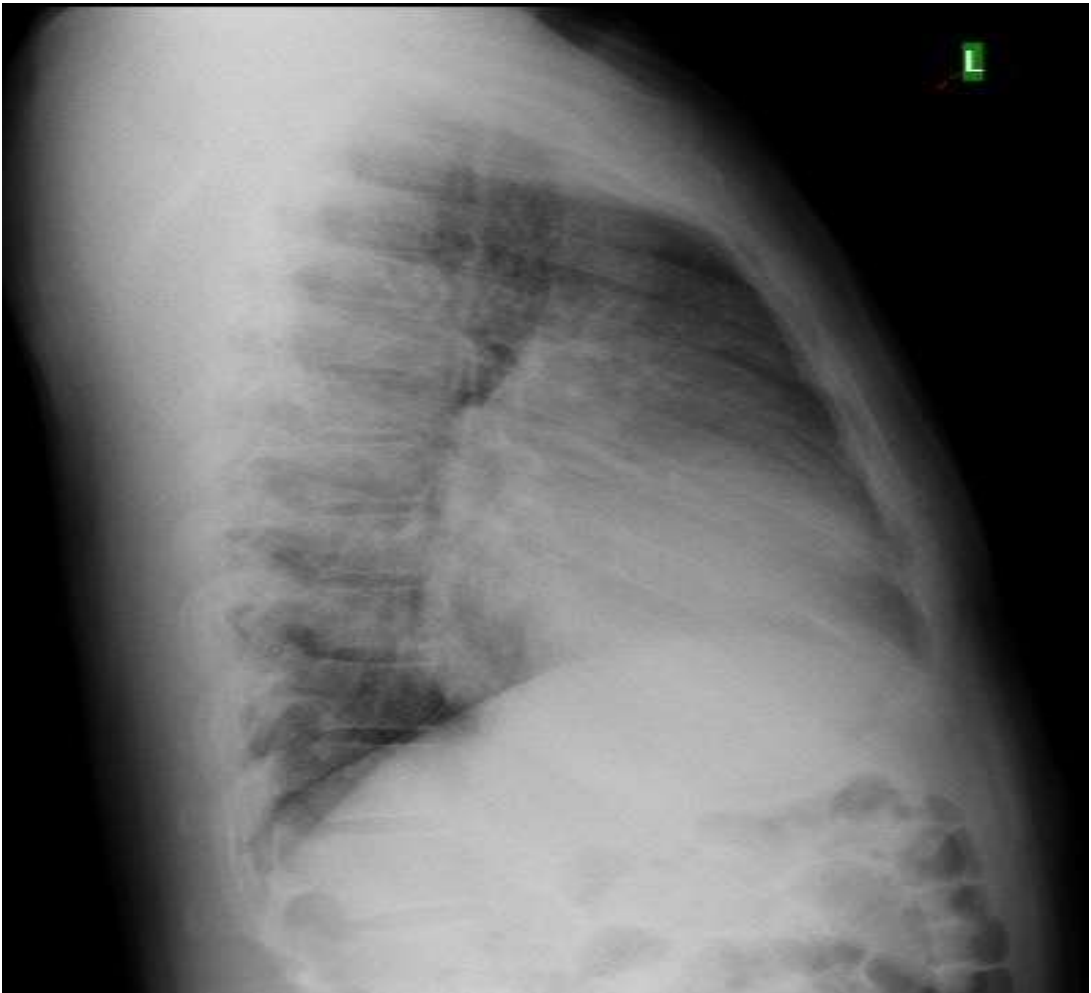
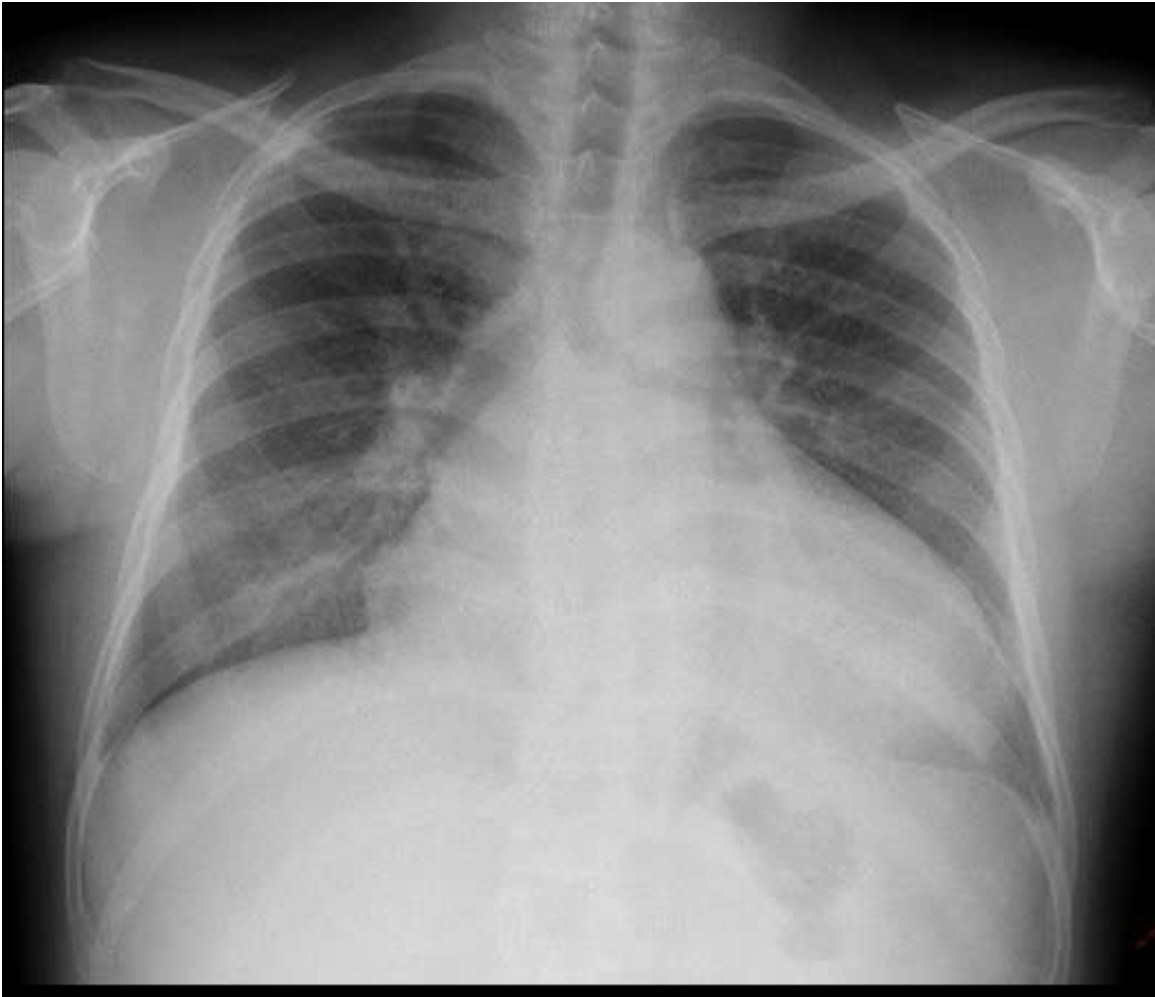
Fleischner's sign- prominent central pulmonary artery

Approach to X Ray in CCHD

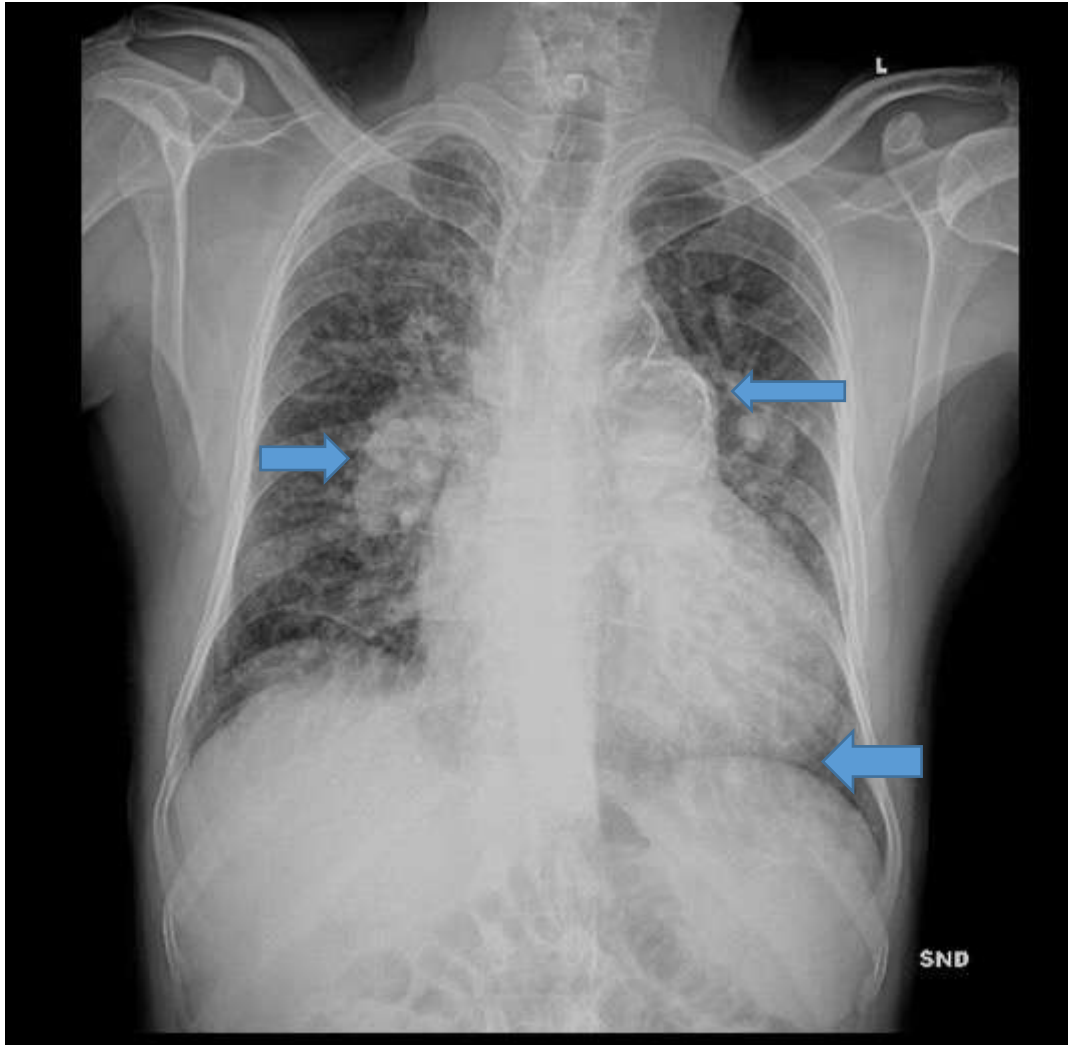


Can you identify this X-Rays???

32 M/Fatigue and Palpitations since 2 months



68/>, H/o cyanosis since 40 years, recent DOE,differential clubbing



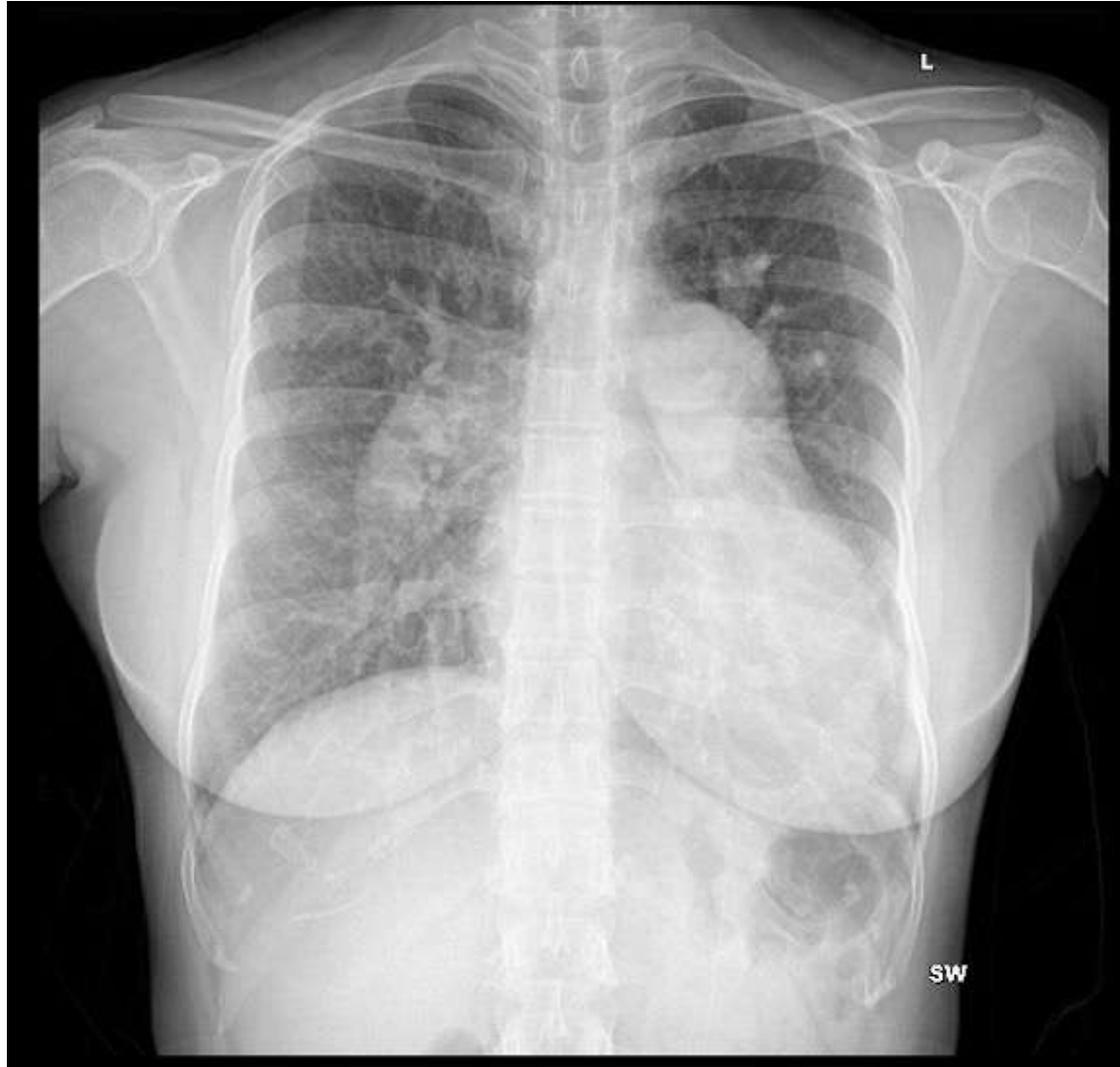
Post tricuspid shunt Eisenmenger with degenerative AS

Case of AP window Eisenmenger syndrome with degenerative AS

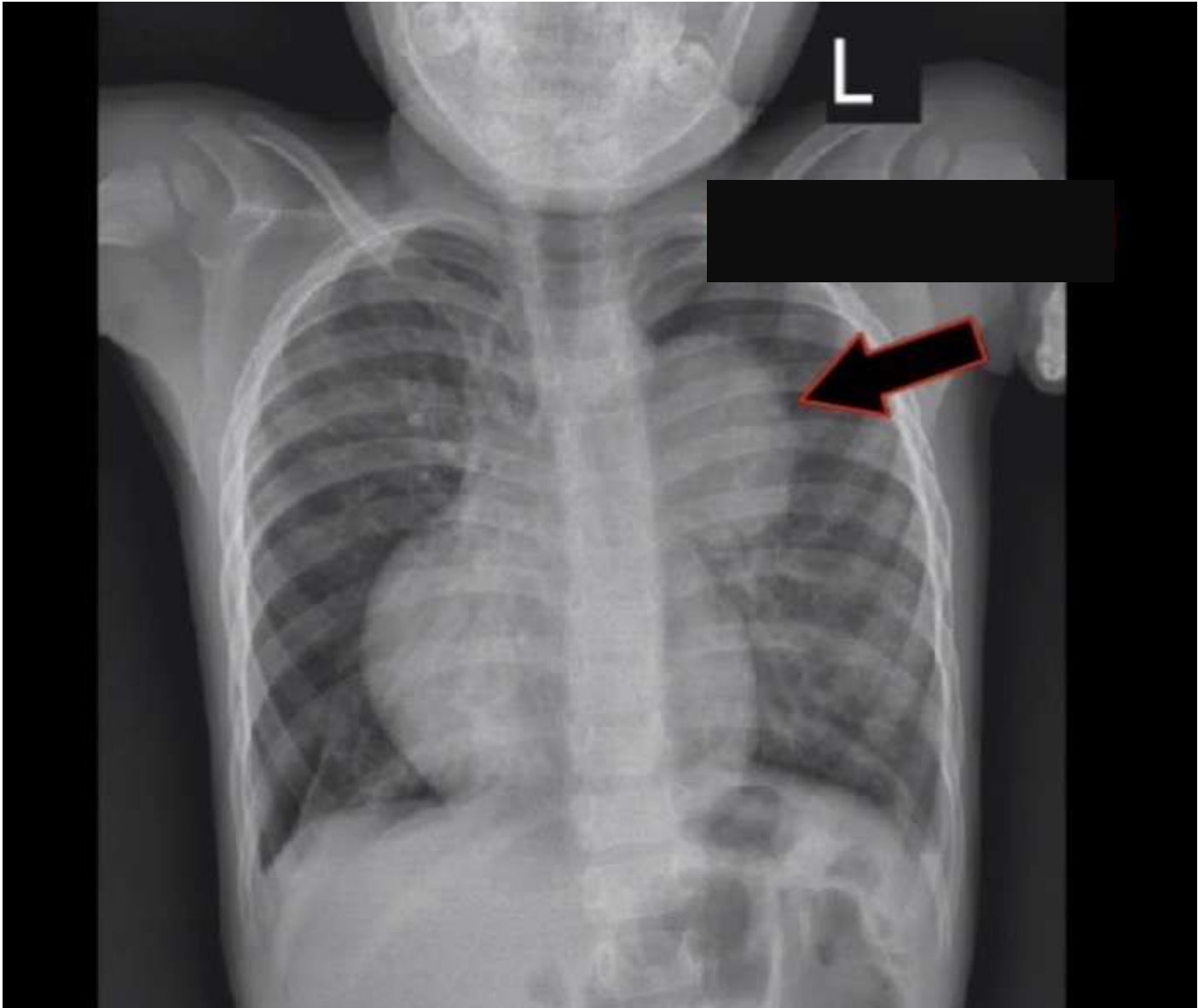
Causes of calcification in MPA includes

1. Eisenmenger syndrome
2. PDA(Cap of Zinn)
3. Severe Pulmonary artery hypertension(rarely)
4. Metastatic pulmonary artery calcification

32/F, Dyspnea and recurrent LRTI, no cyanosis



TOF patient with loud “to and fro murmur”

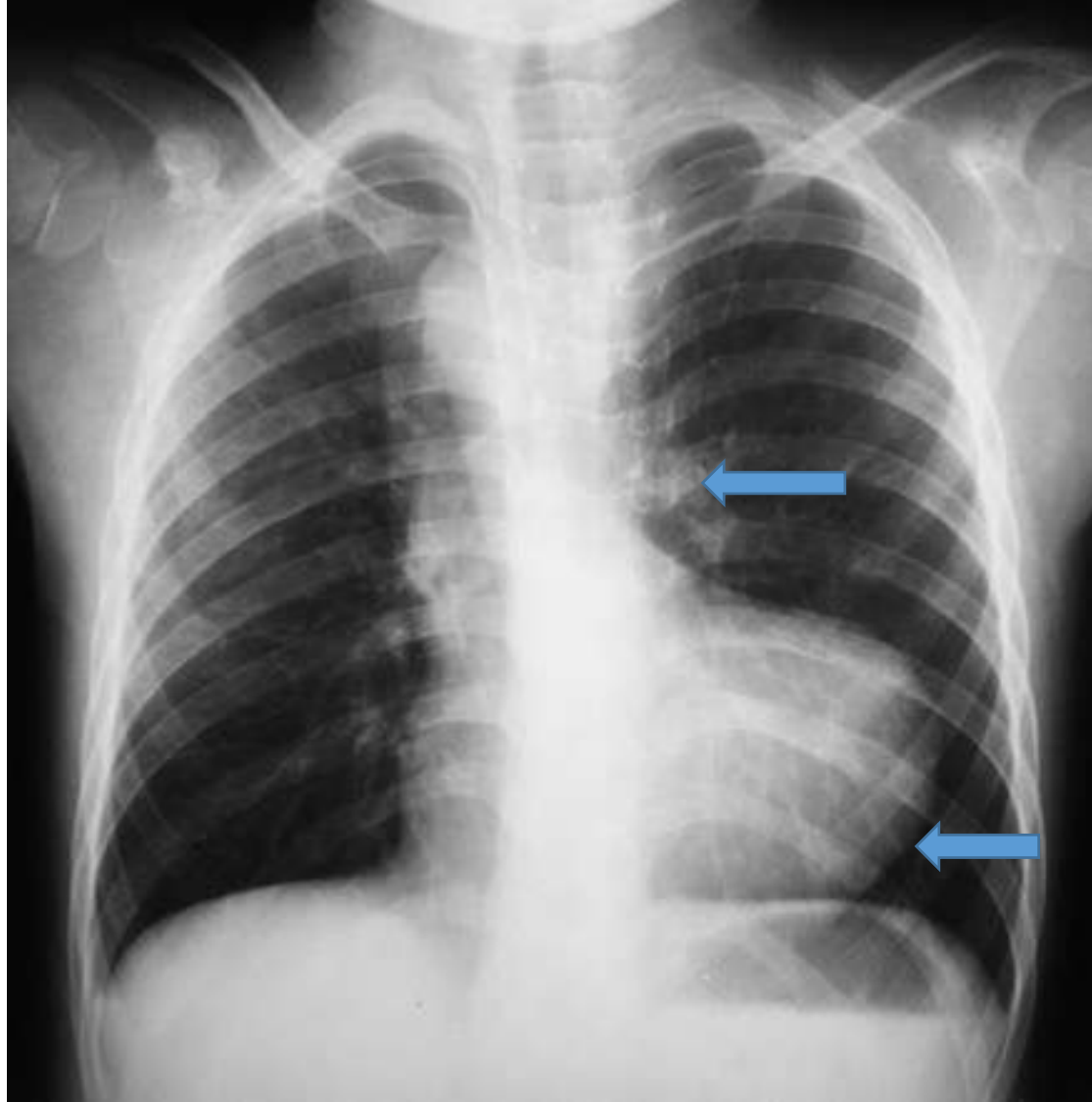


TOF with absent pulmonary valve syndrome

- **Causes of aneurysmal dilatation of MPA includes**

1. Eisenmenger syndrome
2. TOF with Absent pulmonary valve
3. Idiopathic dilatation of pulmonary artery
4. Primary pulmonary hypertension
5. Connective tissue ds, rheumatologic ds
6. Infectious ds like TB, Syphilis

23/M, cyanosis since childhood and silent precordium



CXR in TOF – Salient features

- Normal sized heart(may be enlarged in pulmonary atresia)
- Boot shaped heart(horizontal IVS producing straight upper portion and convex and rounded infero-lateral portion of LV apex and concave upper left heart border due to pulmonary and infundibular hypoplasia)
- Pulmonary oligemia
- Right aortic arch in 25 % patients
- Absent thymic shadow(Di George syndrome) with indentation on leftward positioned trachea-bronchial shadow
- Dilated Ascending Aorta

TOF Physiology

X Ray Findings

**DORV WITH
SUBAORTIC VSD AND PS(TOF LIKE)**

TOF LIKE CXR

SUBPULMONIC VSD (TGA LIKE)-→NO PS

CARDIOMEGALY, PLETHORA,PROMINENT PULMONARY TRUNK

TOF WITH ABSENT PULMONARY VALVE

ANEURYSMAL DILATATION OF MPA, NORMAL PULMONARY VASCULARITY

TOF WITH PULMONARY ATRESIA

MAY HAVE CARDIOMEGALY, LACY RETUCULAR PATTERN(COLLATERALS), HIGH INCIDENCE OF RIGHT AORTIC ARCH(VS PA WITHOUT VSD)

d TGA VSD PS

EGG ON SIDE (MILD CARDIOMEGALY WITH NARROW VASCULAR PEDICLE DUE TO AP RELATIONSHIP OF GREAT VESSEL AND ABSENT THYMIC TISSUE)

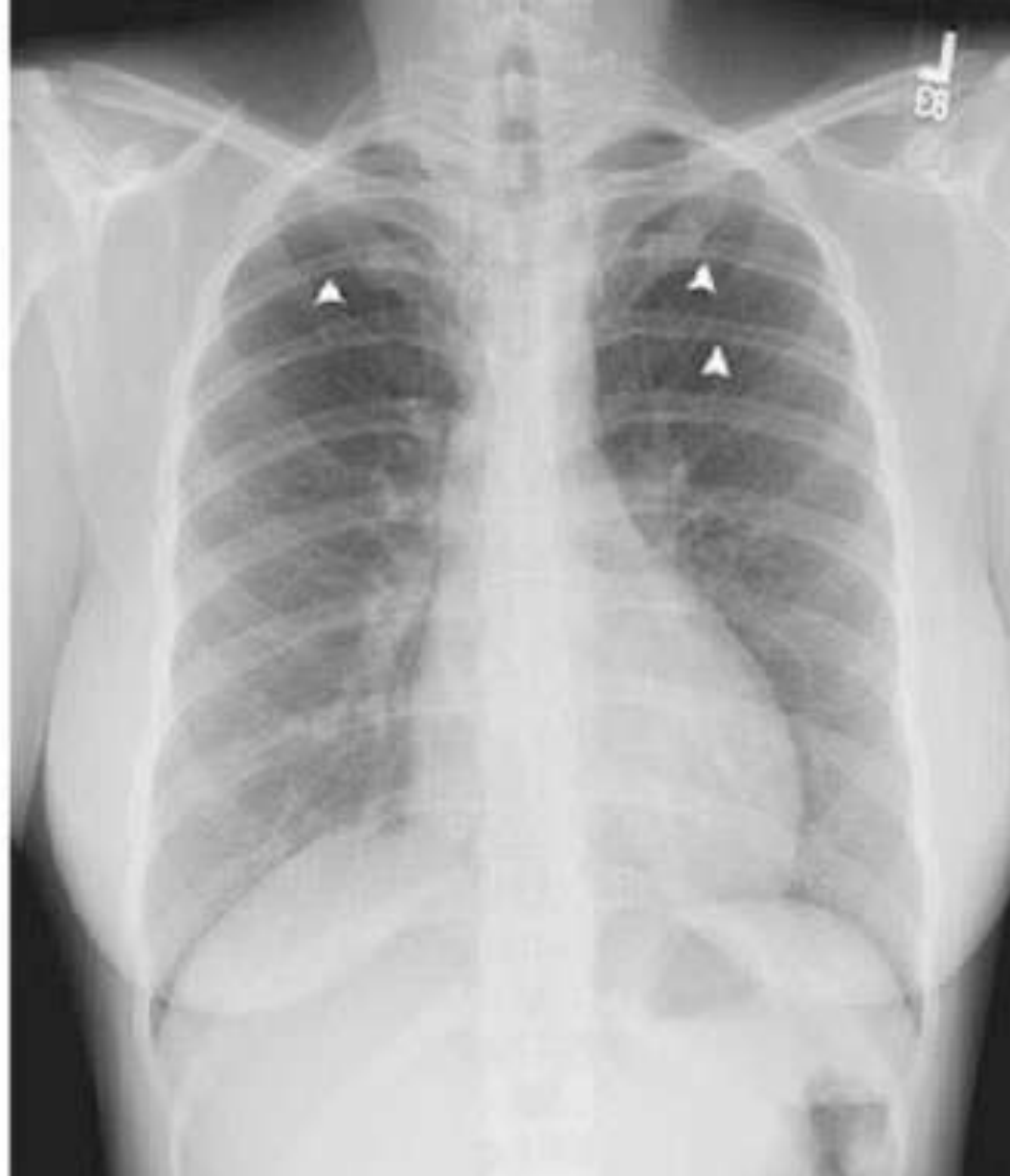TRICUSPID ATRESIA VSD PS

CARDIOMEGALY WITH LV APEX, RA ENLARGEMENT, OLIGEMIA, MPA NOT PROMINENT, PROMINENT ASC AORTA

SINGLE VENTRICLE VSD PS

NORMAL SIZED HEART, OLIGEMIA, CONVEX SHADOW ON LEFT UPPER BORDER DUE TO INVERTED RUDIMENTARY CHAMBER GIVING ORIGIN TO AORTA.

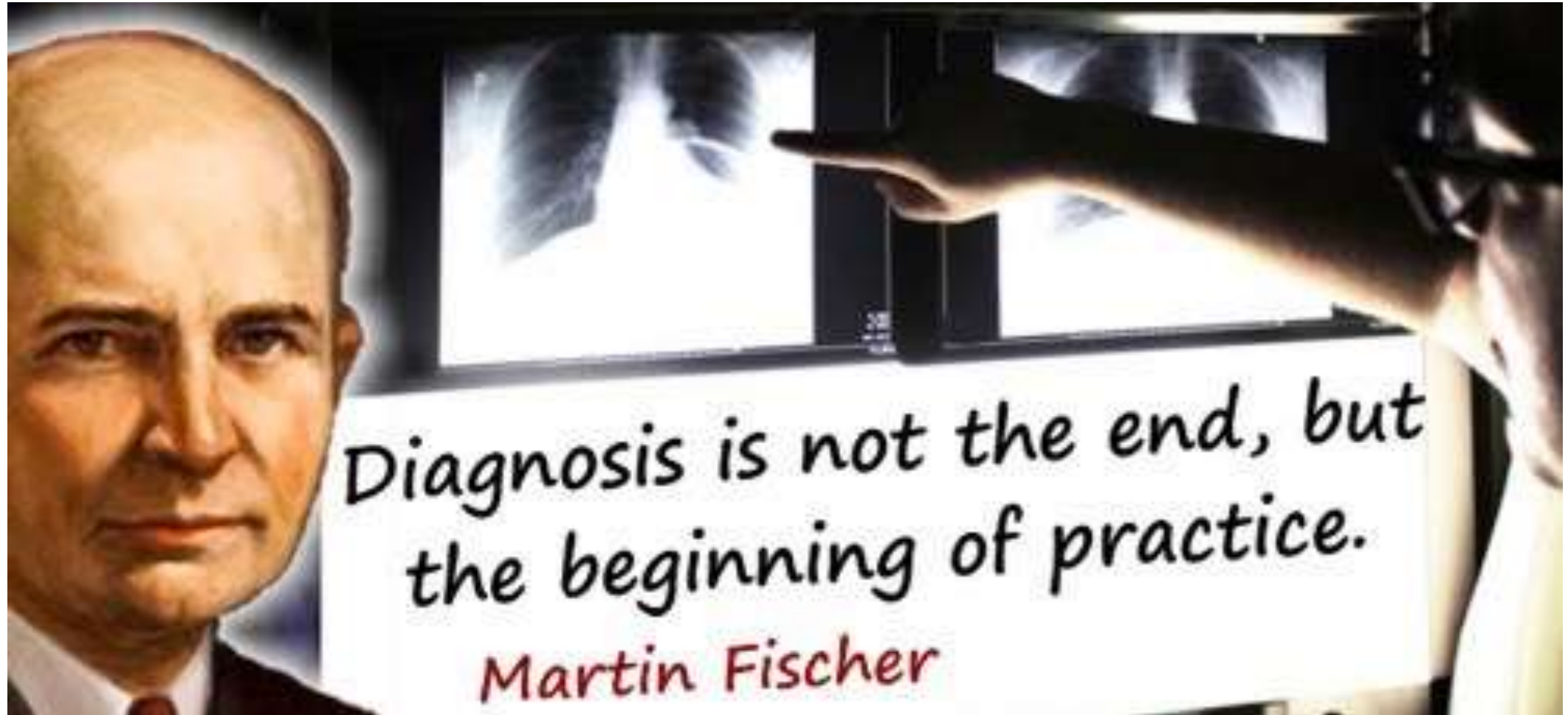
32/M, HYPERTENSION WITH CONTINUOUS MURMUR ON BACK



Coarctation of Aorta(post subclavian)

- **Causes of rib notching**

1. CoA (post subclavian)
2. Classical BT shunt(unilateral)
3. SVC obstruction(collateral intercostal venous dilatation)
4. Thrombosis of abdominal aorta(notching of lower ribs)
5. Neurofibromatosis
6. Intercostal AV fistula



Diagnosis is not the end, but
the beginning of practice.

Martin Fischer